



Tissue engineering in dentistry

James C. Earthman, BS, MS, PhD^{a,*}, Cherilyn G. Sheets, DDS^b,
Jacinthe M. Paquette, DDS^b, Ronald M. Kaminishi, DDS^c,
W. Peter Nordland, DMD^d, Robert G. Keim, DDS, GdD^e,
Jean C. Wu, BSc, MSc, DDS^b

^a*Departments of Chemical Engineering and Materials Science, Biomedical Engineering, and Orthopedic Surgery,
University of California, 916 Engineering Tower, Irvine, CA 92697-2575, USA*

^b*Newport Coast Oral Facial Institute, 360 San Miguel Dr., Ste. 204, Newport Beach, CA 92660, USA*

^c*14343 Bellflower Blvd, Bellflower, CA 90706, USA*

^d*850 Prospect Street, La Jolla CA 92037, USA*

^e*Department of Orthodontics, University of Southern California, 925 West 34th St., Room 312E,
Los Angeles, CA 90089-0641, USA*

Overall orofacial appearance and function can be enhanced by a range of treatment options, ranging from simple to complex. Simple procedures with a powerful esthetic impact include tooth whitening, porcelain bonded restorations, esthetic tooth recontouring, interproximal bonding of composite materials, and traditional crowns and bridges. As esthetic oral facial needs become more complex due to malocclusions, dentofacial asymmetry, trauma, periodontal disease, tooth/bone loss, and the general effects of aging, a more integrated approach is indicated. Treatment may primarily involve the prosthodontist/restorative dentist, or it may involve a multidisciplinary team of dental and medical specialists.

This article discusses dentistry's contributions to tissue engineered occlusal function and facial beauty. We highlight the contributions possible from prosthodontics, oral maxillofacial surgery, periodontal plastic microsurgery, dental engineering, and oral biologic treatment in the near future. To better place each contribution in perspective, a general prosthodontic overview is required.

Prosthodontics

The loss of natural teeth poses the greatest hazard for mutilation and destruction of part of the facial skeleton with accompanying distortion of the appearance, morphology, and function of the soft tissues [1]. Teeth are lost from decay, trauma, and periodontal disease, or they may be congenitally missing. According to the Surgeon General's Report on Oral Health, by age 17 years more than 7% of the population is missing at least one permanent tooth. By age 50, the average American is missing 12 teeth. One third of those over the age 65 are missing all their teeth [2]. Accompanying the tooth loss is a loss of the supporting bone/tissue complex surrounding the teeth resulting in a loss of facial soft tissue support.

Prosthodontics includes the entire spectrum of dental health restorative procedures that restore the effects of hard and soft dental tissue loss. The focus of prosthodontic specialty care is to restore and maintain a patient's oral function and esthetic appearance by the repair or replacement of missing teeth or oral structures with artificial devices. Dentists have been successful in treating patients with depleted or missing natural teeth. As the chief diagnostician involved in the rehabilitation of complex multidisciplinary dental reconstructions, the restorative dentist or prosthodontist must guide the co-specialists involved in the coordination of treatment to ensure idealized treatment results [3]. A

* Corresponding author.

E-mail address: earthman@uci.edu (J.C. Earthman).

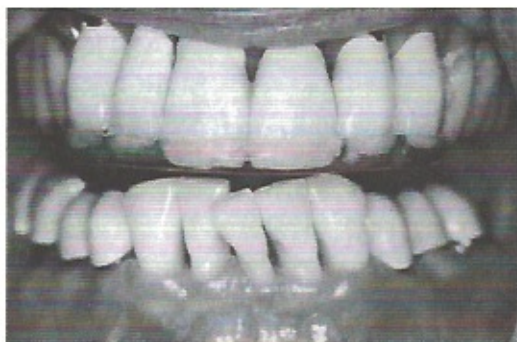

Fig. 1. Intraoral view of a patient in need of oral rehabilitation. The patient exhibited a severe loss of periodontal support and exaggerated drifting and tipping of the remaining mandibular teeth.

high level of involvement becomes especially important in the correct placement of dental implants, pre-prosthetic surgeries, hard tissue engineering, and treatments with a strong esthetic component.

Fig. 1 presents an intraoral view of a patient in need of oral rehabilitation. The patient exhibited a severe loss of periodontal support and exaggerated drifting and tipping of the remaining mandibular teeth. An occlusal view of the patient's mandibular arch after extraction of the remaining mandibular teeth and endosseous implant replacement is shown in Fig. 2. Note the thin residual ridges, which resulted from many years of progressive periodontal disease. An occlusal view of the same patient (Fig. 3) with the completed implant supported restoration provides this patient with a stable, esthetic result able to withstand the masticatory loads equal to that of the natural dentition. Fig. 4 is an intraoral view of the reconstructed patient. The appropriate vertical dimension of occlusion has been restored for improved overall esthetics and function. An extra-oral view of the same patient (Fig. 5) demonstrates the effectiveness with which a fixed-implant reconstruction can restore a patient's proper lip and facial support for an esthetic and natural appearance to the entire dentofacial complex.

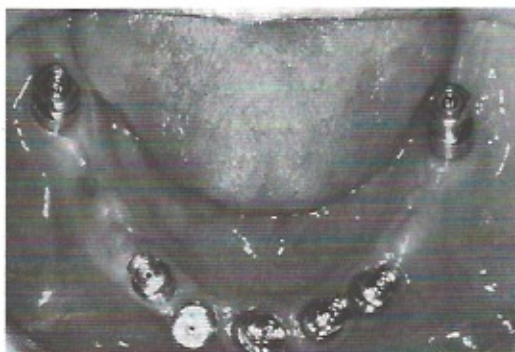

Fig. 2. An occlusal view of the mandibular arch of the patient in Fig. 1 after extraction of the remaining mandibular teeth and endosseous implant replacement. Note the thin residual ridges that resulted from many years of progressive periodontal disease.

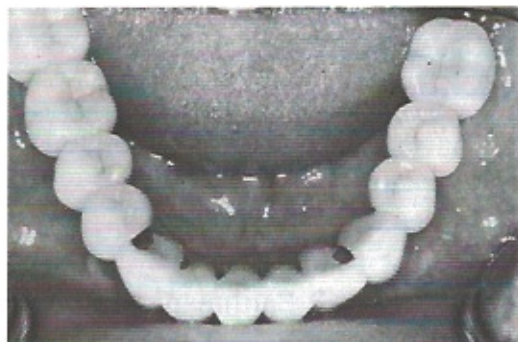

Fig. 3. An occlusal view of the patient in Fig. 1 with the completed implant restoration, which provides this patient with a stable, esthetic result able to withstand the masticatory loads equal to that of a natural dentition.

Historically, extensive or complete loss of natural dentition was restored with removable appliances. Although this treatment was successful in the immediate replacement of lost teeth and supportive bone, continued use of removable dentures is accompanied by ongoing bone loss of the underlying ridges and excessive torquing forces on the remaining dentition, with resultant tooth loss. Maxillomandibular morphologic changes take place slowly over a number of years and depend on the balance of osteoclastic and osteoblastic activity. Even with the best efforts put forth in the creation of stable and balanced removable appliances, osteoclastic activity prevails, and loss of bone

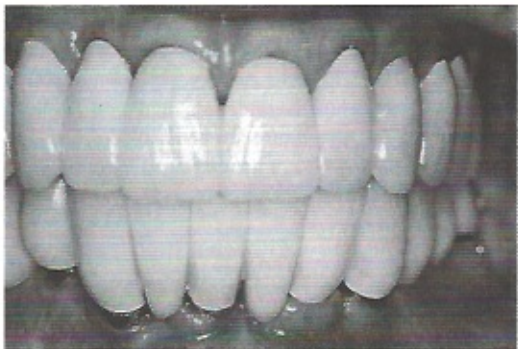

Fig. 4. Intraoral view of the full reconstruction with the appropriate vertical dimension of occlusion established for improved overall esthetics and function.

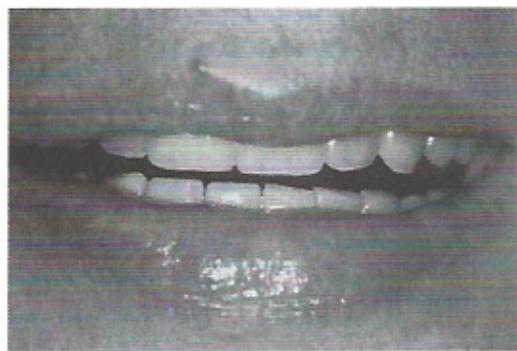

Fig. 5. An extra-oral view of the patient in Fig. 1 illustrates the effectiveness with which a fixed-implant reconstruction can restore a patient's proper lip and facial support for an esthetic and natural appearance to the entire dentofacial complex.

occurs. The compromised residual ridges cause a reduction in the total face height and an increase in disfiguring mandibular prognathism [1]. A negative cycle of destruction of oral structures is then perpetuated.

In the natural dentition, the periodontium attaches the teeth to the jaws, providing a suspensory apparatus resistant to functional forces. It allows the teeth to adjust their position when under stress while maintaining appropriate bony support. When tooth loss occurs, an implant-supported prosthesis can potentially provide a functional and esthetic reconstruction, provided the implants are precisely placed in the predetermined location and angulation. The accuracy of implant placement is important in the anterior aspect of the mouth and when the remaining bone is limited in quantity and quality. Computed tomography and precise surgical guides assist the surgeon in proper placement to compliment the restorative dentist's efforts in creating a natural restoration [4]. However, even with ideal implant placement, the advantages of the periodontal attachment of tooth to bone are lost because implants attach directly to the bone, eliminating the soft tissue supporting apparatus.

Increasingly, immediate implant placement is being recommended. Some of the benefits include factors such as maximization of the natural healing process, minimizing bone resorption, minimal implant site preparation, a reduction in the number of surgical stages, a potential simplification in the design and construction of the prosthesis, and the immediate positive psychological effect on the patient [5].

The overall goal in prosthetic dental treatment is to create a natural appearance to the dentition and the underlying supportive tissues and bone while showing no visible signs of missing or restored teeth. When biologic means of restoring tissues are not enough,

prosthetic replacement of missing oral structures is required. The evolution of restorative materials available continues to assist the restorative dentist in creating life-like restorations. These advancements have been predominantly in the arena of porcelain systems and have made the replication of natural-looking tooth structures increasingly achievable. Additionally, the more recent introduction of bonded ceramic restorations represents a conservative, reliable, and effective procedure to restore extensive coronal volume and length in the anterior and posterior dentition [6].

Fig. 6 shows a pre-operative view of a patient before her dental reconstruction. The loss of vertical dimension of occlusion and compromised facial support can be seen in the thin, down-turned lips and a "saggy" appearance to the lower face. A lateral view of the same patient (Fig. 7) further illustrates the loss of proper facial support evidenced by the prognathic appearance of the mandible. Fig. 8 is a close-up view of the patient's lips at rest, illustrating the esthetic compromises resulting from inadequate lip support provided by the underlying inadequate restorations. A close-up view of the same patient after the dental reconstruction is shown in Fig. 9. The patient's upper lip appears full and wrinkle-free due to the idealized size, form, and position of the underlying new restorations. Fig. 10 shows the same patient after the dental reconstruction. The proper vertical dimension of occlusion established by the new restorations creates a more balanced, youthful appearance for the patient. The continued evolution of porcelain systems available provides the restorative dentist with the ability to recreate natural, vital, and biologically sound restorations (Fig. 11).

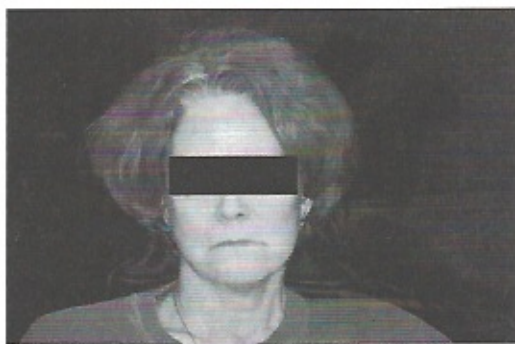

Fig. 6. A preoperative view of a patient before her dental reconstruction. The loss of vertical dimension of occlusion and compromised support of facial tissues can be seen in the thinned, down-turned lips and a "saggy" appearance to the lower face.

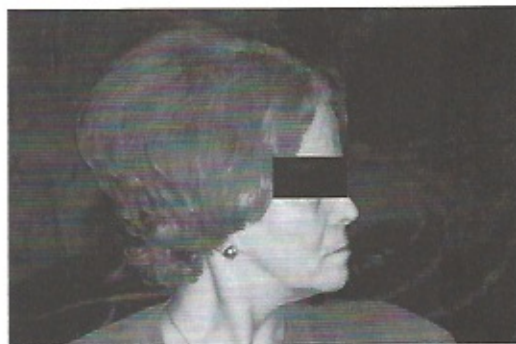

Fig. 7. A lateral view of the patient in Fig. 6 further illustrates the loss of proper facial support evidenced by the prognathic appearance of the lower mandible.

The greater challenge to the prosthodontist lies in the replication of underlying hard and soft tissue structures. When these defects are present, tissue manipulative and regenerative procedures provide the best results in combination with restorative procedures. Communication in treatment planning and treatment sequencing among the co-specialists involved is paramount to treatment success.

Oral and maxillofacial surgery

Osseous reconstruction has been a major emphasis in oral surgery since the 1950s, although the term "tissue engineering" is relatively new. The osseous structures of the face and jaws provide the platform upon which all dental, periodontal, and soft tissue orofacial structures function. Tissue engineering in dentistry begins with the alteration or augmentation of bone with various types of osteotomies, grafts, or implants. Soft tissues, such as the lips, chin, or nose

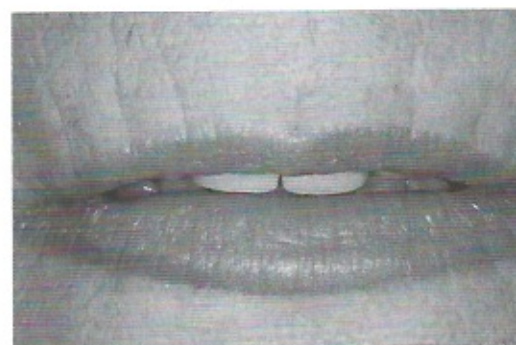

Fig. 8. A close-up view of the patient's lips at rest illustrate the esthetic compromises that can result with inadequate lip support provided by the underlying pre-existing restorations.

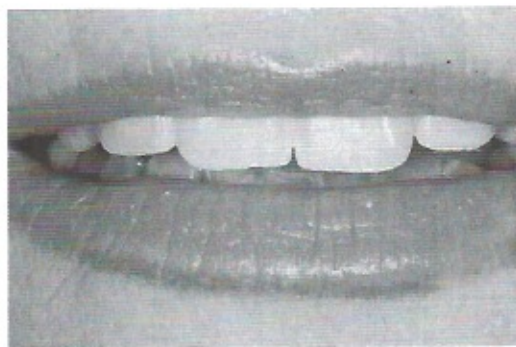


Fig. 9. A similar close-up view of the patient in Fig. 6 after the dental reconstruction. The patient's upper lip appears full and wrinkle-free due to the proper size, form, and positioning of the underlying new restorations.

down to the interdental papilla, cannot attain optimal functional and esthetic excellence without proper osseous or hard tissue support. A reliable and commonly used osseous tissue engineering procedure is the osteotomy. Altering existing bone with osteotomies can create or prepare the foundation for excellent esthetic results.

Different types of grafts are widely used in hard tissue alteration. Autologous bone, fresh cadaver, and mineralized and demineralized lyophilized bone have been used for many years for grafting total face and jaw reconstruction to periodontal pocket defect [7,8]. Since the 1970s, calcium hydroxylapatite has come into widespread use [9]. More recently, porous hydroxylapatite has become one of the most commonly used xenografts.

The most current innovation is the development of osseous inductive and conductive techniques, from the use of platelet-rich plasma to the development of bone

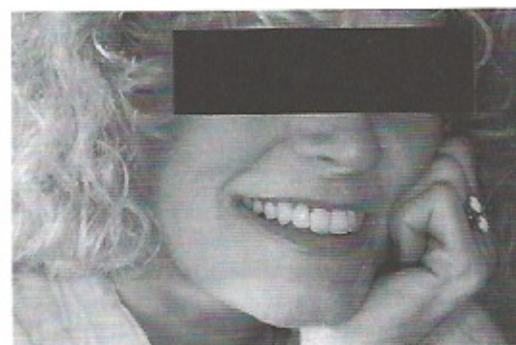

Fig. 10. The same patient as in Fig. 6 after the dental construction. The proper vertical dimension of occlusion of the new restorations creates a more balanced, youthful appearance for the patient.

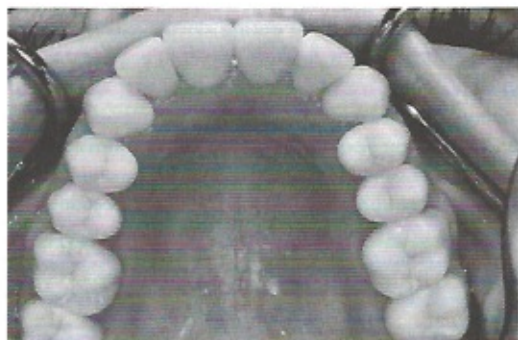

Fig. 11. The continued evolution of porcelain systems available for the creation of dental restorations provides the restorative dentist with the ability to recreate a natural, vital, and biologically sound replacement.

morphogenic protein [10]. Distraction osteogenesis has recently been rediscovered. It has been used for maxillary expansion for about four decades and is now being used more for other facial and long bones. These new innovations are still in their developmental phases.

The long-face maxillary vertical hyperplasia type deformity creates many challenging esthetic problems.

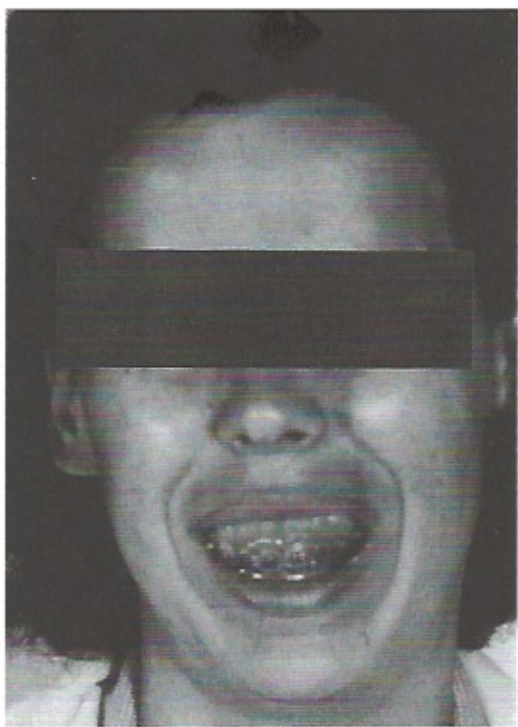

Fig. 12. Pre-operative patient with maxillary vertical hyperplasia.

Abnormal facial proportion, soft tissue elongation, excessive maxillary display, and pronounced facial grimacing to compensate for major lip incompetency are a few examples. Correction of the skeletal dysplasia can create dramatic esthetic improvements in many areas of the face and teeth. A "high Le Fort I" osteotomy can reestablish a proper skeletal foundation [11]. Many esthetic changes occur because the skeletal structure is idealized, and further soft tissue and cosmetic procedures have better results and long-term stability. Fig. 12 shows a patient with maxillary vertical hyperplasia. Fig. 13 is a diagram of the high Le Fort I maxillary intrusion surgical procedure. The post-operative result is shown in Fig. 14 with establishment of normal facial dimensions.

The exploding aging population presents a difficult problem of restoring skeletal support for esthetic enhancement. Patients who wear dentures for a long period of time may lose the majority of the maxilla or mandible through degeneration and bony resorption [7]. Fig. 15 demonstrates how much the face is affected by loss of the maxilla, alveolar bone, and teeth. Severe changes occur in the oral facial structures, including the upper lip, cheeks, nasolabial area, nose, and alar base (Fig. 16). Reconstructive bone grafting of the maxilla can be done with subsequent teeth replacement with crowns or dentures over dental implants (Fig. 17). Major esthetic improvements can be created via dental and soft tissue facial procedures. The results are

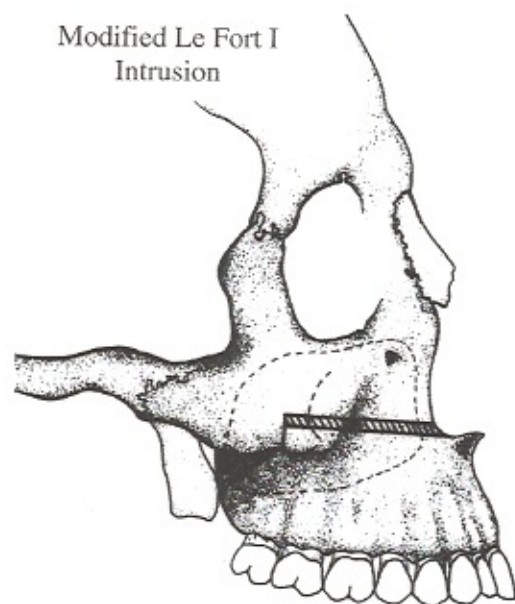


Fig. 13. High Le Fort I maxillary intrusion surgical procedure.

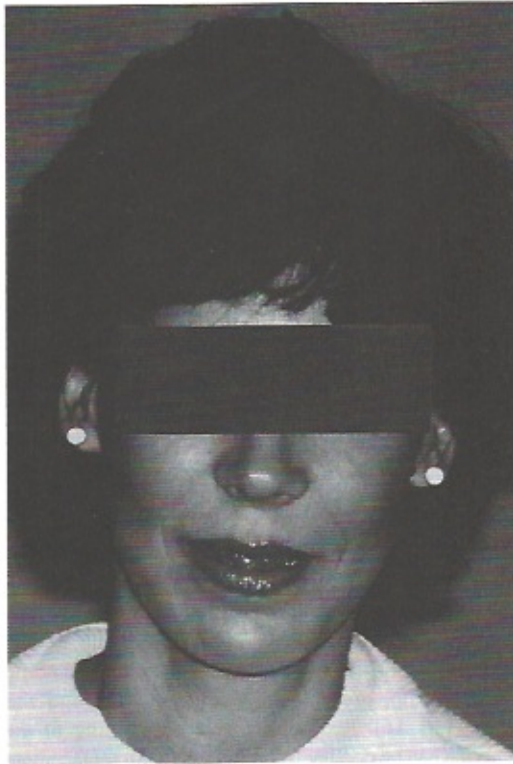

Fig. 14. Post-operative result with normal facial dimensions.

superior, more stable, and long lasting due to the solid osseous scaffolding.

Skeletal considerations should be the primary focus in dental tissue engineering because the bone creates the foundation. An ideal skeletal foundation facilitates beautiful esthetic surgical creations and enhances and prolongs the long-term stability of soft tissue procedures. There are many ways to reconstruct and augment the osseous structures of the face and jaws. Among these methods, a recent biomechanical approach involving controlled bone remodeling is discussed.

Biomechanics of dental tissues and restorative materials

Periodontal structures are subjected to loading conditions that can have a dramatic effect on the remodeling of tissues, particularly in the case of bone. The loading can be relatively static, where it is held steady or changes slowly, or dynamic (pulsatile), in which the loading rates are relatively high. Dynamic impact forces can result from occlusion (such as chewing hard foods), from parafunctional activity

(bruxing and clenching during sleep), and from traumatic impact by a foreign object. These forces are generated by muscular contraction and the kinetic energy (masses and relative velocities) associated with the impacting bodies. By contrast, static forces result primarily from slow or persistent muscle contraction. Thus, dynamic forces can be much greater than naturally occurring static forces in the periodontium and, therefore, have potentially greater long-term effects.

Wolff [12] is given credit for recognizing that mechanical stresses are responsible for the architecture of bone. His "law of bone transformation" implies that a mathematical relationship can be drawn between mechanical stresses and the formation of bone. Consistent with this law, Fung [13] proposed a biomechanical stress-growth relationship, asserting that stable bone growth occurs under an intermediate range of stresses (Fig. 18). In deriving this relationship, it was recognized that (1) transport of matter depends on the strain of the cell membranes, (2) actin-myosin cross-bridges in the cell membranes are sensitive to strain, and (3) chemical reaction rates within the cell depend on stress. Fung suggested that there is a point at which optimal stress leads to a maximum in the growth rate. Furthermore, an amount of stress below and

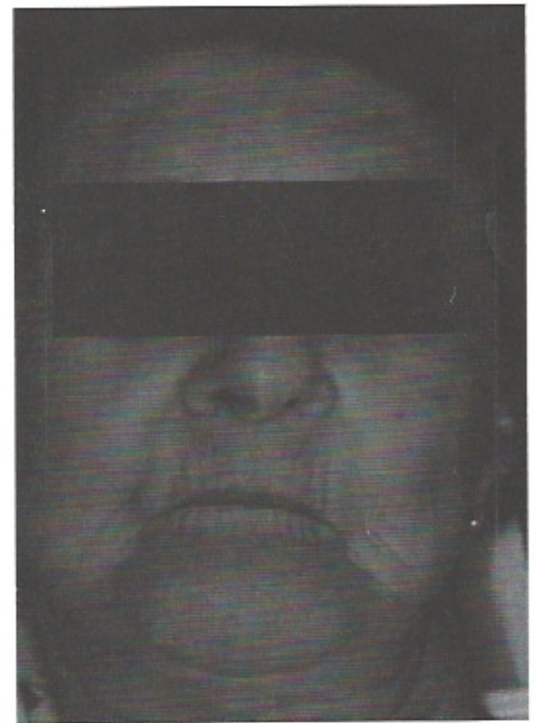

Fig. 15. Pre-operative patient with severe maxillary degeneration.

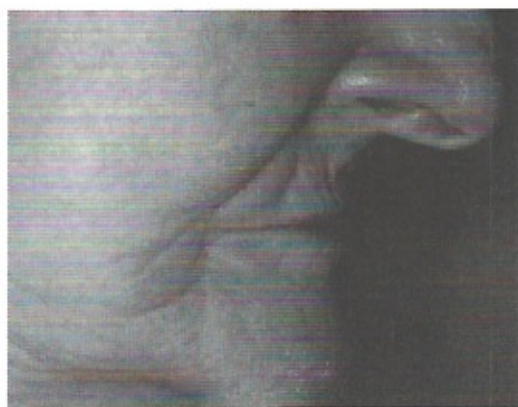

Fig. 16. Note loss of nasal and labial support due to severe bone loss.

above certain thresholds leads to resorption. This hypothesis implies that bone loss can result from excessively low or high load levels. Muscle and bone have been shown to atrophy during periods of immobility and relatively low skeletal loading [13,14]. By contrast, over-tightening a metal screw implanted in bone, for example, can also lead to resorption as a result of the damage induced [13].

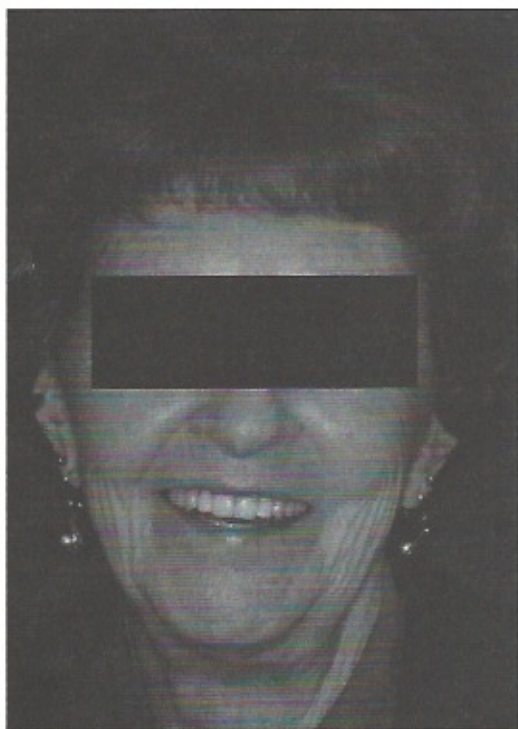

Fig. 17. Post-operative result after bone grafting and denture construction.

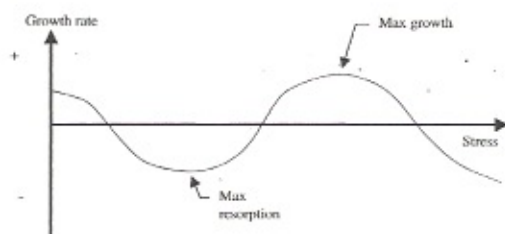


Fig. 18. Fung's Stress-Growth relationship [13]

Takakuda [15] proposed that mechanotransduction in bone is not a function of simple agitation at the cellular level but is a complex cascade of events. The outside stimulus for these events is transduced via the fluids acting within the bone and in the extracellular matrix that then initiates the release of growth factors by osteoclasts. This release induces bone growth by osteoblasts. This process accounts for remodeling under the relatively low levels of dynamic strain known to occur in human bone cells. Fluid forces have also been credited for triggering osteoblastic activity through shear stresses that induce electric potentials or gene-regulated response elements [16-19]. These fluid forces require repeated motion induced by dynamic loading to stimulate a significantly prolonged remodeling response. Under static loading, the fluid forces rapidly dissipate and remain near zero until the load is suddenly altered.

Orthodontic movement has for many years been instigated with the application of a static force. However, the static force in this case acts to bias the naturally occurring dynamic forces in the desired direction. The greater sensitivity to dynamic or fluctuating forces is important for avoiding fatigue damage processes driven by repeated dynamic loading without wasting resources on unnecessary bone growth under prolonged application of static forces.

Dynamic loading effects have been investigated in a number of studies in the field of prosthetic dentistry [20-26]. Implant-borne dental prostheses are generally made of materials that undergo reversible elastic deformation under occlusal loading, storing and transmitting almost as much mechanical energy as is input to the system. By contrast, the periodontal ligament in the natural tooth complex acts as a shock absorber, undergoing anelastic deformation, which dissipates a significant amount of the available mechanical energy. A schematic comparison of energy conservative versus energy dissipative behaviors is illustrated in Fig. 19. This dissipation of energy is generally effective in reducing the dynamic loading rate and the peak force. In other words, greater dissipation of the input kinetic energy results in lower and more slowly

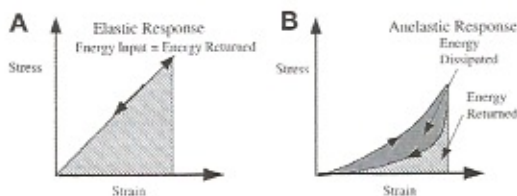


Fig. 19. Energy conservative elastic deformation (A) and energy dissipative anelastic deformation (B) plotted as stress versus strain. The amount of energy dissipated can be determined from the amount of potential energy, equal to the area under the curves that is returned to the system upon unloading. For purely elastic deformation, loading and unloading follow the same path (reversible) so that the energy returned is equal to the energy input.

imposed impact forces. Static forces are typically limited by factors that are not affected much by energy dissipation during the initial application of the static load, such as muscle strength. Pointing to the dichotomy in behaviors between implants and natural teeth, researchers have attributed the intrusion of natural tooth abutments to the inability of dental prostheses to provide a biocompatible level of energy dissipation [23]. For example, tooth intrusion in partial implant supported prostheses (Fig. 20A) has been attributed to these forces stimulating the resorption of bone. Tooth intrusion can be reversed (Fig. 20B) by increasing the damping capacity of the implant-supported superstructure so that the impact forces are reduced [25]. Thus, excessive or insufficient mechanical stimulus can instigate a bone remodeling response to reposition a tooth abutment until it receives a compatible range of dynamic forces from the implant structure.

Based on a study where implants were used as an orthodontic anchorage [27], the bone neighboring an implant seems to remodel at different dynamic load levels compared with those for natural teeth. This difference is possibly due to the effect of the periodontal ligament of the natural teeth on bone remodeling. The movement of natural teeth by bone remodeling allows a healthy tooth to shed excessive dynamic loads to the other teeth, making the load distribution more uniform. Alternately, a tooth under lower-than-normal loads emerges by growth of the underlying bone, allowing it to take up its share of the occlusal loading.

The above findings indicate that mechanical biocompatibility of dental prosthetics is an important factor for achieving optimum results. Mechanical biocompatibility refers to the evasion of unwanted physiologic changes and promotion of desired tissue growth and stability by optimizing the mechanical properties of synthetic materials in contact with the biologic structure. Mechanical biocompatibility not

only depends on static properties, such as Young's modulus, but also on the dynamic response of the material characterized by its damping capacity. Adjusting the damping capacity of synthetic materials, such as those in an implant structure, can have a substantial effect in reducing the strain rate experienced in the surrounding biologic tissues. Because strain rate has been shown to be a factor that is prominent in governing bone remodeling, damping capacity must be addressed in prosthesis development for optimum tissue engineering during restoration.

Orthodontics

Generally known simply as "orthodontics," the official definition of the dental specialty known as Orthodontics and Dentofacial Orthopedics includes the diagnosis, prevention, interception, guidance and correction of malrelationships of the developing or mature orofacial structures [28]. Most commonly associated with "braces," orthodontics deals with the corrections of malocclusions by means of fixed or removable appliances that move teeth, their supporting

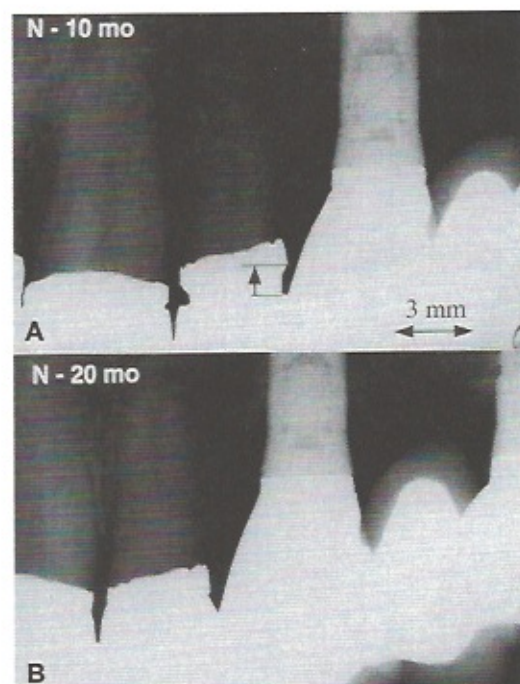


Fig. 20. (A) Tooth intrusion (arrow) for a parafunctional patient at 10 months after placing the partial implant supported superstructure [23]. (B) Reversal of tooth intrusion at 20 months by increasing the damping capacity of the prosthesis [25].

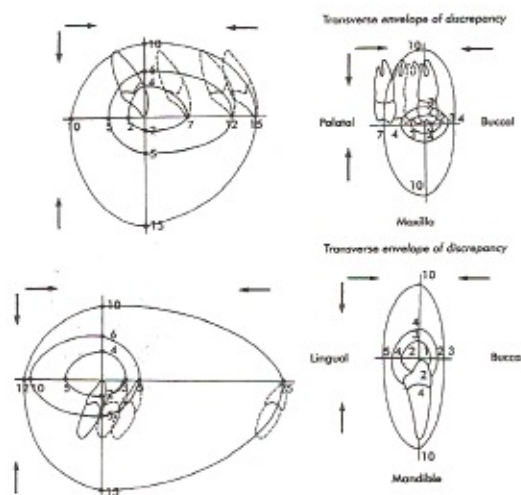


Fig. 21. Proffit's envelope of discrepancy.

bone, and surrounding periodontal tissues. Apparent tooth movement can be achieved by moving the teeth through the surrounding tissues or, in the growing patient, by re-directing the vectors of facial growth so that the bones of the face, especially the mandible and the maxilla, grow in favorable directions. Most treatments in growing patients involve orthodontic movement (ie, movement of teeth alone) and orthopedic movement (ie, movement of the jaws and bones of the face). Alternatively, in the nongrowing patient (ie, adult patients), surgical intervention may be necessary to reposition the bones of the face into the positions that would have resulted had facial growth been more favorable.

Many patients seek the services of an orthodontist to straighten crooked teeth, whereas others want to "fix a bad bite." Both are valid reasons for seeking care. Although the majority of patients seeking care

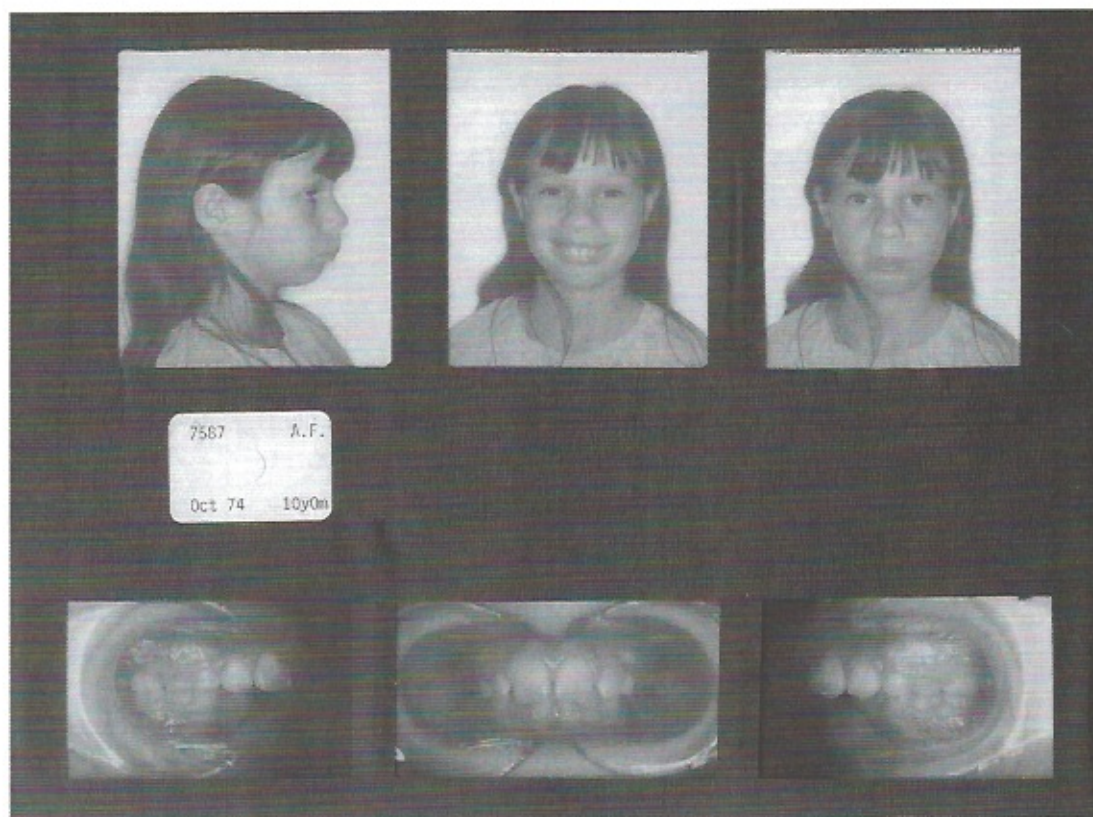

Fig. 22. Ten-year-old female patient demonstrating significant mandibular retrusion, maxillary protrusion, and lip incompetence. Orthodontic treatment consisted of two separate phases. Phase I involved extraction of the upper deciduous cuspids, upper deciduous first molars, and the developing permanent first bicuspid. The premaxillary segment was then retracted with fixed appliances and a high pull J-hook headgear. (Courtesy of John Digiulio, MD, Arcadia, CA.) (See also Color Plate 4).

do so for esthetic reasons, functional indications for orthodontic treatment should not be underemphasized. Superficially combining an esthetic smile with a physiologically unsound occlusion (or, more simply, artificially combining a pretty smile with a bad bite) is a sure recipe for later occlusal dysfunction and therapeutic disaster.

Orthodontic treatment planning, therefore, is a matter of identifying a specific list of esthetic and functional problems, derived from clinical examination data, analysis of articulated study models, and quantitative anatomic radiographic analyses, referred to as cephalometric analyses. The next step is to logically apply established treatment modalities to address those specific problems. For example, a protrusive maxilla (an upper jaw that is too far forward relative to the mandible and cranial base when the patient is viewed in profile) calls for appliance therapy that retards forward growth of the maxilla while allowing or stimulating forward growth of the mandible. This is possible as long as the patient is actively

growing. A similar situation in a nongrowing patient may dictate a combination of orthodontic and surgical treatment modalities.

Just how much is possible in terms of orthodontic treatment? There are four basic approaches available to the orthodontist [29]:

1. Repositioning the teeth through orthodontic tooth movement
2. Redirection of facial growth through functional alteration or the use of strong modifying forces
3. Dentofacial orthopedics in which dentofacial (dentoalveolar) growth is altered through the use of strong modifying forces
4. Surgical-orthodontic treatment

Proffit et al [30] have proposed what they term an "envelope of discrepancy for the maxillary and mandibular arches in three planes of space" (Fig. 21). They note that "for any characteristic there are three ranges of correction: (1) a range of correction that can be

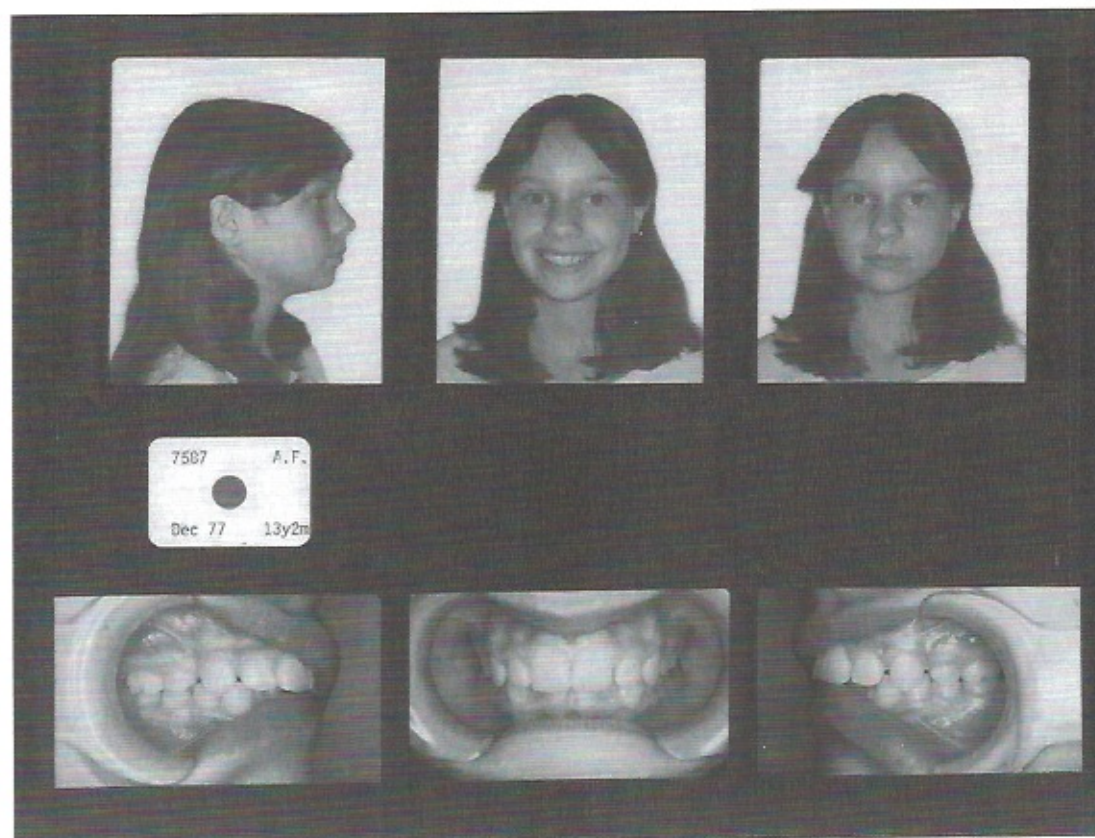

Fig. 23. Same patient at the end of phase 1, age 13 years, 2 months. Note the marked improvement of the soft tissue and mandibular profile. Lip competence has been achieved. (Courtesy of John Digiulio, MD, Arcadia, CA.) (See also Color Plate 5).

accomplished by orthodontic tooth movement alone; (2) a larger range of correction that can be achieved by tooth movement plus functional or orthopedic treatment; and (3) a still larger range of correction that requires surgery as a part of the treatment plan."

The range of correction by orthodontic means alone is about the same for adults as it is in children. As children become adults, the ability to achieve skeletal correction through orthopedic growth modification declines and vanishes. For the nongrowing individual, corrections of malocclusions greater than that possible through tooth movement alone require a combination of orthodontics and orthognathic surgery.

The envelope of discrepancy is not symmetric. Greater corrections can be made by orthodontics and dentofacial orthopedics in the sagittal plane than in the transverse or vertical planes. A much greater degree of maxillary protrusion can be treated orthodontically than can a similar problem in the mandible. Although they are not absolute limits, the guidelines suggested by Proffit et al [30] serve as useful guides in answering

the question posed above. By orthodontic means alone, maxillary incisors can be retracted approximately 7 mm. They can be advanced only 2 mm. The same teeth can be extruded 4 mm but intruded only 2 mm. In a growing individual, when orthodontic forces are combined with orthopedic and functional forces, the maxillary incisors can be retracted 12 mm, advanced 5 mm, extruded 6 mm, and intruded 5 mm. When surgery is performed in addition to orthodontics, as in a nongrowing patient, the maxillary incisor can be retracted 15 mm, advanced 10 mm, extruded 10 mm, and intruded 15 mm. In the mandible, the incisor can be retracted 3 mm by orthodontic tooth movement, advanced 5 mm, extruded 2 mm, and intruded 4 mm. Using orthodontics and orthopedics together, the incisor can be retracted 5 mm, advanced 1 mm, extruded 5 mm, and intruded 6 mm. When surgery is used, the incisor can be retracted 25 mm (via mandibular set back), advanced 12 mm, extruded 15 mm, and intruded 10 mm [30]. The transverse envelope of discrepancy is much smaller than is the sagittal envel-

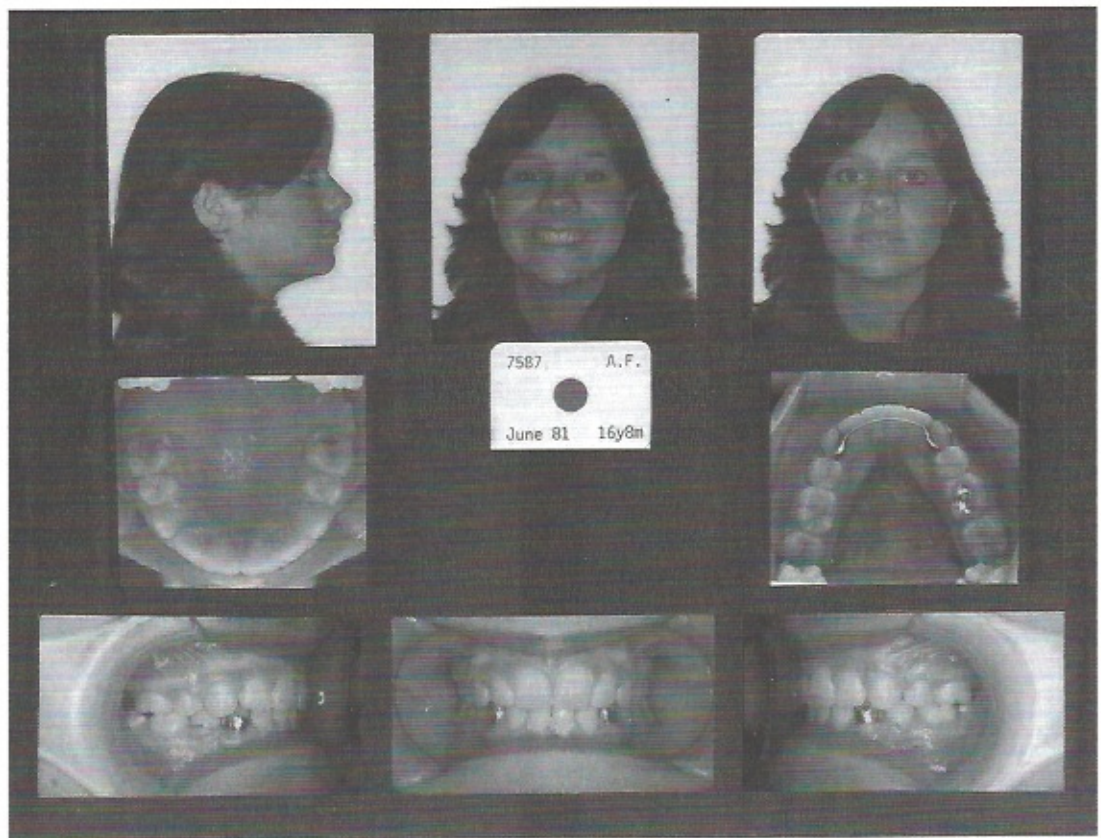

Fig. 24. Same patient at the end of phase 2, age 16 years, 8 months. Treatment consisted of fixed appliance therapy with extraction of lower first bicuspsids. (Courtesy of John Digiulio, MD, Arcadia, CA.) (See also Color Plate 6).

ope. Orthodontically, maxillary premolars can be moved buccally 3 mm, palatally 2 mm, intruded 3 mm, and extruded 2 mm. Orthopedically, maxillary premolars can be moved buccally 4 mm, palatally 3 mm, intruded 4 mm, and extruded 3 mm. Surgically, they can be moved buccally 7 mm, palatally 4 mm, intruded 10 mm, and extruded 10 mm. Mandibular premolars have similar restraints with buccal movement of 2 mm, lingual movement of 1 mm, intrusion of 3 mm, and extrusion of 2 mm being possible through orthodontics; buccal movement of 4 mm, lingual movement of 2 mm, 4 mm intrusion, and 4 mm extrusion is possible through orthopedics. Surgery increases the possible values to 5 mm buccal, 3 mm lingual, 10 mm intrusion, and 10 mm extrusion.

Numerous authors, including Holdaway [31,32], Gencov [33], and Subtelny [34], have explored the relationship of the change in lip and soft tissue position relative to the underlying tooth movements. Although there is disagreement between the various authors, it is safe to assume that the relationship is about 1:1 for the

upper lip relative to change in sagittal position of the upper incisor. That is, if the upper incisor is retracted about 2 mm, the upper lip moves back a similar amount (Figs. 22–25).

Orthognathic surgery (ie, surgery intended to correct the skeletal relationships of the face and mouth) is almost always done in conjunction with orthodontics. Typically, the patient seeks the care of an orthodontist who, on recognizing a skeletal discrepancy beyond the scope of orthodontics alone, refers the patient to an oral and maxillofacial surgeon. Working together, the orthodontist and the surgeon plan out an overall course of treatment that results in maximal facial esthetics and harmonious occlusal function. Typically, the orthodontist positions the teeth in the correct positions relative to their own jaw (ie, upper teeth are positioned correctly within the maxillary arch, and lower teeth are positioned in correct relationship to the mandibular arch). This process generally takes 18 to 24 months. The maxillofacial surgeon then positions the maxilla and mandible in the correct positions relative to each

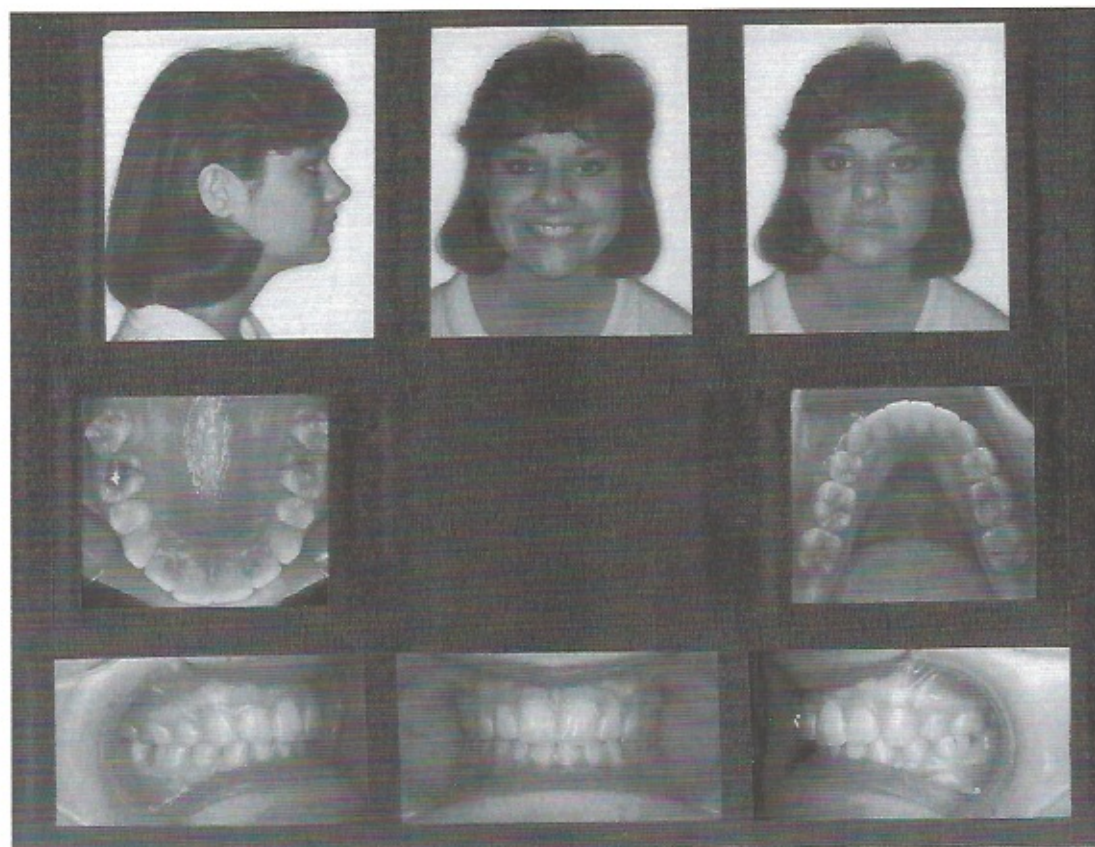


Fig. 25. Same patient post-retention, age 20 years, 7 months. (Courtesy of John Digiulio, MD, Arcadia, CA.) (See also Color Plate 7).

other and the cranial base. After the surgical episode, the orthodontist finalizes the occlusion, a process that generally takes another 4 to 6 months.

Whether in conjunction with surgery or not, orthodontics is capable of effecting dramatic changes in the facial appearance and occlusal function (Figs. 26 and 27).

Periodontics

Oral plastic surgery is as different from oral surgery as plastic surgery is to general surgery in medicine. Reconstructive and regenerative oral plastic surgical procedures can be divided into soft tissue (gingiva and mucosa) and hard tissue (tooth and bone) categories. Additionally, the incorporation of the surgical dissecting microscope and microsurgical instrumentation has allowed the surgeon the capability of fine-tuning surgical procedures. Although implant dentistry has

had a marked impact for the potential replacement of missing teeth and bone regeneration has become predictable, much advancement has been gained recently through the soft tissue plastic surgical procedures available.

Pedicle grafts and free grafts

Pedicle grafts have an inherent advantage over free grafts because of their intact vascularity; however, free grafts have become popular due to several modifications that have enhanced their predictability and esthetic value [35]. Predictability has been enhanced by increasing vascularity to donor tissues through the sandwiching of donor tissues [36]. The handling of small delicate tissues has been aided with the use of the surgical dissecting microscope and microsurgical instrumentation [37]. Previously, free grafts had blood supply from only their base, which contacted the recipient tissue bed, and donor cells that

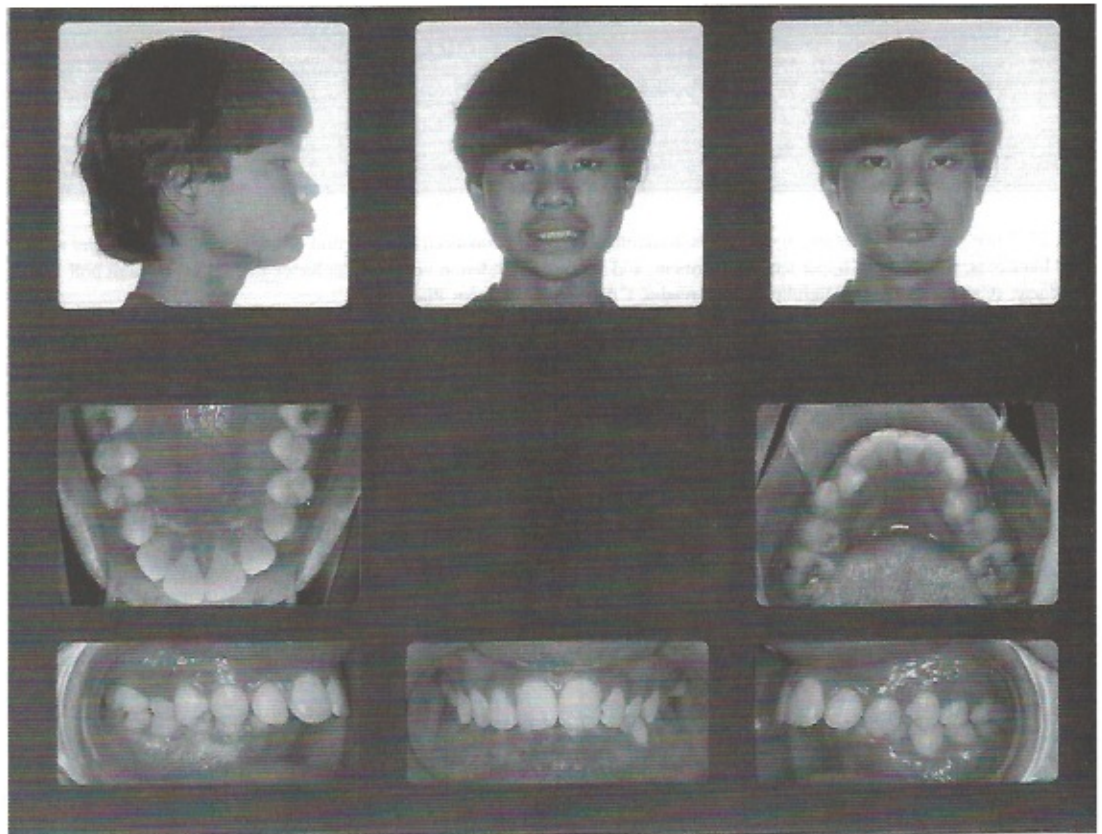


Fig. 26. Male patient aged 14 years 10 months demonstrating extreme overjet or "buck-toothedness"; overclosure; spacing and crowding of the dentition; lip incompetence; and eversion of the lower lip, mandibular retrusion, and maxillary protrusion. (Courtesy of John Digulio, MD, Arcadia, CA.) (See also Color Plate 8).

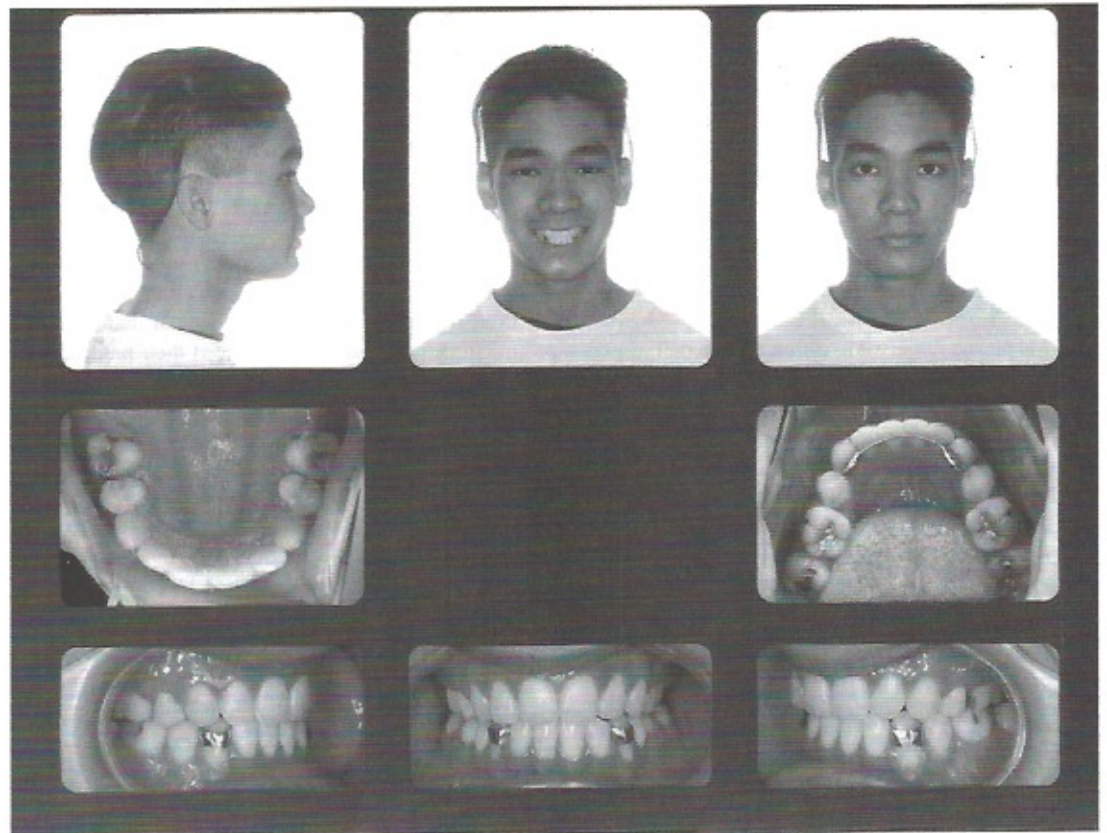


Fig. 27. Same patient in retention, age 17 years, 8 months. Treatment consisted of extraction of upper second molars and all four first bicusps, retraction of upper anterior segment, and space consolidation via fixed appliance therapy and a high pull J-hook headgear. (Courtesy of John Digiulio, MD, Arcadia, CA.) (See also Color Plate 9).

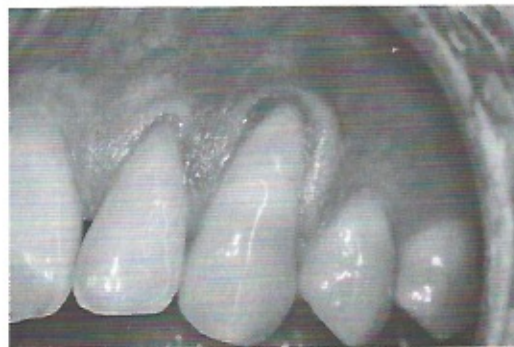

Fig. 28. Pre-operative site showing gingival recession of the upper left canine. (See also Color Plate 10).

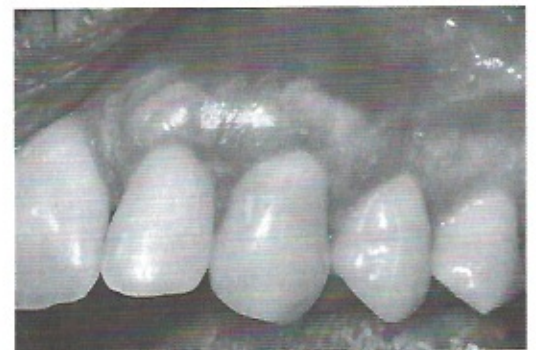

Fig. 29. Area of gingival recession corrected with a free gingival graft demonstrating consistent color and texture. (See also Color Plate 11).

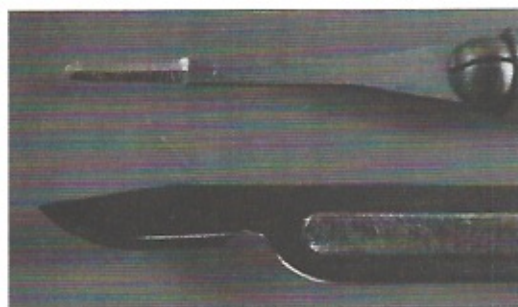


Fig. 30. Microsurgery scalpels are significantly smaller than the traditional 15-C scalpel.

resided a distance from a vascular supply suffered the greatest chance of necrosis. Current techniques take advantage of surrounding the graft almost entirely with blood supply, thereby improving the survivability of all the transplanted cells. Esthetic color blending and natural surface textures are maintained in the recipient area because the surface tissues are unchanged and keep their original appearance. An example of gingival recession is shown in Fig. 28. Fig. 29 illustrates the post-operative result after free gingival grafting. Ideally, transplanted tissue is positioned with the same connective tissue fiber orientation, as it would be in situ. Microsurgery allows the manipulation of tissues with minimal access incisions and trauma. Microsurgical scalpels are significantly smaller than even the traditional 15-C scalpel blades (Fig. 30). Enhanced visibility and the elimination of releasing incisions are possible with the use of small bendable micro-scalpels. Microsurgical procedures to restore soft tissue esthetics and esthetic restorative dentistry can combine their treatment modalities to create normal appearing smiles that are severely disfigured. Loss of soft tissue between the upper

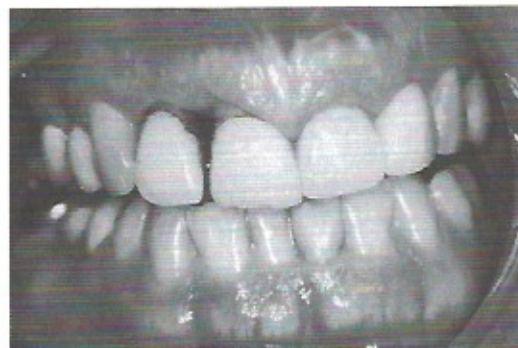

Fig. 31. The pre-operative defect after of soft tissue between the upper right lateral and central incisors. (See also Color Plate 12).

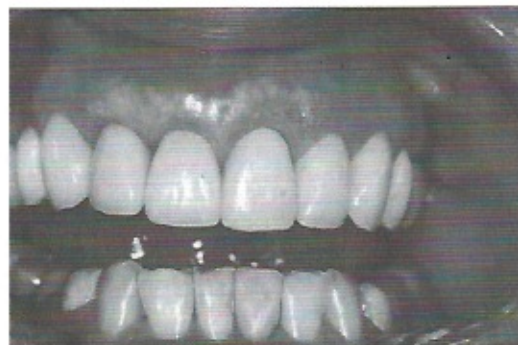

Fig. 32. The post-operative result after free gingival grafting and restoration with porcelain fused to gold restorations. (See also Color Plate 13).

right lateral and central incisors is shown in Fig. 31. After a free gingival graft to restore soft tissue esthetics, the area was restored with porcelain fused to gold crowns (Fig. 32).

Applications

Gingival recession

Gingival recession exposes root dentin, which is much softer than enamel and can be susceptible to tooth brush abrasion and potential sensitivity to hot, cold, sweets, and touch. Ideally, root coverage corrective procedures should not only replace the lost gingiva esthetically but should regenerate the functional attachment to the previously denuded root surface. An example of generalized root recession is shown in Fig. 33. Fig. 34 illustrates the result after a root coverage corrective procedure. Detoxification with root planing and acid demineralization of the exposed root surface has been shown to expose root dentin collagen fibrils. Graft collagen fibers can attach

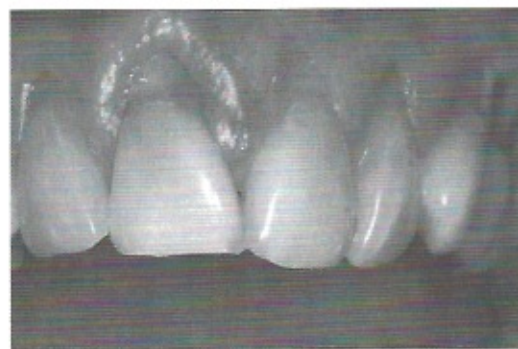

Fig. 33. Generalized gingival recession exposing root dentin. (See also Color Plate 14).

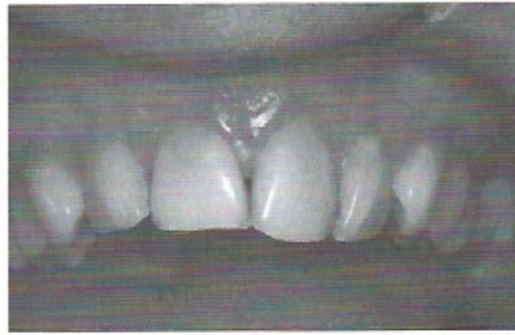

Fig. 34. Root coverage corrective procedure replacing lost gingival and regenerating a functional attachment. (See also Color Plate 15).

to the exposed root surface collagen and recreate a functional tissue attachment [38].

Ridge defects

Ridge defects can occur when the dento-alveolar bone collapses after tooth extraction. This collapse can make it challenging for the restorative dentist to create an esthetic result due to the increased space and can result in a collapse of the lip. If the dentist creates a normal sized replacement tooth with a collapsed ridge, then a dark shadow results from the void. If the void is filled in with prosthetic tooth structure, then it creates visual and facial asymmetry. Ridge plumping to create a normal architecture is achievable using autogenous connective tissue from the patient's hard palate. An example of a ridge defect is shown in Fig. 35. The post-operative appearance after ridge augmentation is

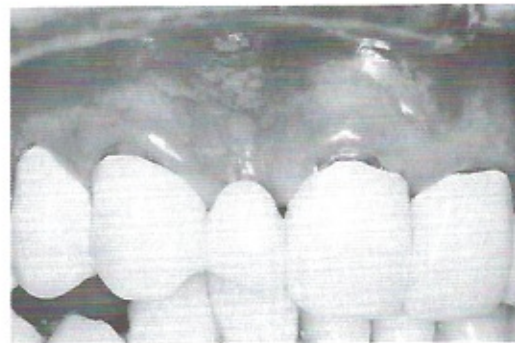

Fig. 35. Ridge defect after extraction of the upper right lateral incisor. (See also Color Plate 16).

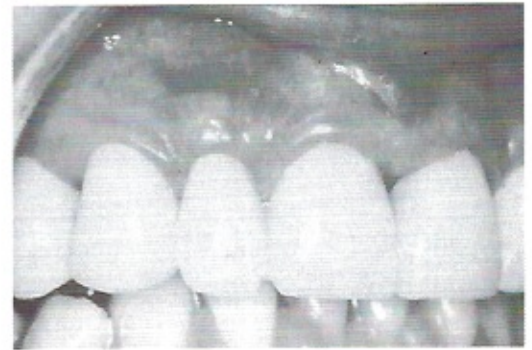

Fig. 36. Ridge augmentation achieved with autogenous connective tissue from the patient's hard palate. (See also Color Plate 17).

shown in Fig. 36. Root coverage procedures and plumping of alveolar ridges have benefited in predictability and esthetics from the sandwiching and microsurgical techniques.

Resective surgery

Resective periodontal plastic surgery can remove excessive gingiva and bone, as is the case with an excessive gingival display. If the enamel of the teeth is covered by gingiva and bone, then the smile can be diminished. Microsurgery to remove precise amounts of gingiva and corresponding alveolar bone can show the full enamel profile of the teeth, which usually creates a bigger, brighter smile. An example of excessive gingival display is shown in Fig. 37. Fig. 38 illustrates the improved esthetics after precise removal of gingival and bone.

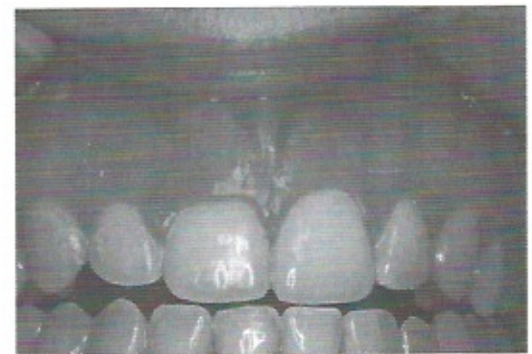

Fig. 37. Excessive gingival display with gingival and bone covering the enamel of the teeth. (See also Color Plate 18).

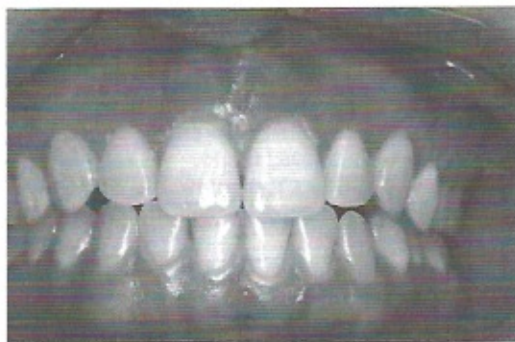

Fig. 38. Precise removal of gingival and bone with microsurgery to reveal more enamel and a more esthetic smile. (See also Color Plate 19).

Oral plastic surgical procedural advances have occurred with the use of microsurgery and technique evolution. There is potential to restore form and function of the soft tissues surrounding teeth after their loss. When there is a developmental excess of tissues, their reduction can be accomplished and thereby enhance individual patient esthetics. Regenerative, reconstructive, and resective procedures can offer enhanced esthetic options.

Future directions

In the past, prosthetic options for tooth replacement included tooth xenotransplantation, allotransplantation, autotransplantation, and dental implants [39]. Despite the improvements in surgical, mechanical, and restorative options, a biologic approach to tooth replacement is desirable [40,41]. With ongoing advancements in experimental embryology, developmental and molecular biology, and biomimetics (the mimicking of biological processes), our prospects for tooth regeneration are becoming a reality.

Significant progress has been made toward defining the events of tooth morphogenesis [42]. It has been demonstrated that cap stage tooth organs can be dissociated into enamel organ epithelial and dental papilla mesenchymal cell samples, which can then be recombined to reestablish tooth morphogenesis *in vitro* [43]. Tissue cultures obtained from tooth explants at the cap stage of development can be used as allografts or xenografts to develop crown and root formations [44].

The pluripotent nature of stem cells holds great promise for the management of a variety of medical and dental conditions. Adult stem cells have greater developmental potential than previously thought and are not reliant on embryonic stem cells [45]. Our

understanding of the molecular regulation of tooth morphogenesis can be applied to manipulate adult stem cells into odontogenic phenotypes. The principle of isolating adult stem cells with odontogenic potential, such as bone marrow stromal fibroblasts, has been established [45]. Bone marrow stem cells derived from mice have been systemically injected to produce hematocytes, heart, brain, lung, liver, muscle, cartilage, and bone tissue [46,47]. The option of stem cell-mediated muscle, dentin, cartilage, and bone regeneration can assist in future tooth replacement through organogenesis.

Odontogenic stem cells have been isolated from adult dental pulp and transplanted into mice. These stem cells produce dentine-like tissue, which holds promise for the regeneration of dentine for tooth repair [48]. Our understanding of the continuously growing mouse incisor model reveals the precise regulatory mechanisms required for epithelial-mesenchymal interaction during morphogenesis [49]. It has been proposed that epithelial stem cells can be harvested from the palate and mesenchymal stem cells obtained from bone marrow or pulp tissue. Using supportive culture media containing the appropriate signaling molecules, a tooth organ can be developed *in vitro*. At the late cap or bell stage of development, the tooth germ can be transplanted into the site of the missing tooth. As tooth development continues, the tooth erupts into occlusion and function. Alternatively, the tooth organ can be cultured to complete crown and root formation and then transplanted into the jaw [50].

Although our understanding of the mechanical and chemical signals regulating epithelial and mesenchymal interactions is incomplete, it seems that adult stem cell mediated tooth regulation is possible.

Summary

Advances in tissue engineering provide an increased level of understanding of the mechanical and chemical stimuli that regulate tissue responses. Oral tissue engineering can be applied to recreate missing osseous or dental structures or correct orofacial deformities, changing the patient's smile, mid-facial height, and the soft tissue drape. Biomechanical principles can also be applied to tissue engineering to enhance the bone/tooth or bone/implant functionality and long-term stability. Advancements are also being achieved in the area of biomimetics that will allow the creation of new biologic replacements for missing oral structures. The opportunity for bioengineering to charter the course of tooth regeneration is an exciting

prospect and will improve the quality of life for patients for decades to come.

Acknowledgments

The authors thank Dean H. Slavkin, School of Dentistry, University of Southern California, for his helpful insight.

References

- [1] Hickey JC, Zarb GA. Boucher's prosthodontic treatment for the edentulous patients. 8th edition. St. Louis: The C.V. Mosby Company; 1980.
- [2] Balshi T, Becker W, Bedrossian E, Wöhrle P. Dental implants. Omaha: Addicus Books; 2003.
- [3] Paquette JM, Sheets CG. Beyond cosmetics—the esthetic rehabilitative patient. *J Calif Dent Assoc* 2002; 30:849–56.
- [4] Cehreli MC, Calis AC, Sahin S. A dual-purpose guide for optimum placement of dental implants. *J Prosth Dent* 2002;88:640–3.
- [5] Balshi TJ, Wolfinger GJ. Immediate loading of dental implants in the edentulous maxilla: case study of a unique protocol. *Int J Periodontics Restorative Dent* 2003;23:37–45.
- [6] Magne P, Perroud R, Hodges JS, Belser UC. Clinical performance of novel-design porcelain veneers for the recovery of coronal volume and length. *Int J Periodontics Restorative Dent* 2000;20:440–57.
- [7] Davis WH, Hochwald DA, Daly B, Owen WF. Reconstruction of the severely resorbed mandible. *J Pros Dent* 1990;64:583–8.
- [8] Fonseca RJ, Davis WH. Reconstructive preprosthetic oral and maxillofacial surgery. 2nd edition. Philadelphia: WB Saunders; 1995.
- [9] Holmes R. Regeneration within a coralline hydroxyapatite implant. *Plast Reconstr Surg* 1979;63:626–33.
- [10] Hochwald DA, Marshall MW. Augmentation of the edentulous maxilla and mandible for implant utilization. *Oral Maxillofac Clin North Am* 1994;6:781–811.
- [11] Kaminishi RM, Davis WH, Hochwald DA, Nelson N. Improved maxillary stability with modified Le Fort I technique. *J Oral Maxillofac Surg* 1983;41:203–5.
- [12] Wolff J. Das gesetz der transformation der knochen. Berlin: A. Hirschwald; 1982.
- [13] Fung YC. Biomechanics: motion, flow, stress, and growth. New York: Springer-Verlag; 1990.
- [14] Vaughan J. The physiology of bone. New York: Oxford University Press; 1991.
- [15] Takakuda K. A hypothetical regulation mechanism of adaptive bone remodeling. *JSME Int J* 1993;36: 417–24.
- [16] Owan I, Burr DB, Turner CH, Qiu J, Tu Y, Onyia JE, et al. Mechanotransduction in bone: osteoblasts are more responsive to fluid forces than mechanical strain. *Am J Physiol* 1997;273:C810–5.
- [17] Rubin J, McLeod KJ, Titus L, Nanes MS, Catherwood BD, Rubin CT. Formation of osteoclast-like cells is suppressed by low frequency, low intensity electric fields. *J Orthopaed Res* 1996;14:7–15.
- [18] McLeod KJ, Rubin CT, Otter MW, Qin Y. Skeletal cell stresses and bone adaptation. *Am J Med Sci* 1998;316: 176–83.
- [19] Ogasawara A, Arakawa T, Kaneda T, Takuma T, Sato T, Kaneko H, et al. Fluid shear stress-induced cyclooxygenase-2 expression is mediated by C/EBP β , cAMP-response element-binding protein, and AP-1 in osteoblastic MC3T3–E1 cells. *J Biol Chem* 2001;276: 7048–54.
- [20] Katona TR, Paydar NH, Akay HU, Roberts WF. Stress analysis of bone modeling response to rat molar orthodontics. *J Biomech* 1995;28:27–38.
- [21] Chapman RJ, Kirsch A. Variations in occlusal forces with a resilient internal implant shock absorber. *Int J Oral Maxillofac Implants* 1990;5:369–74.
- [22] Van Rossen IP, Braak LH, De Putter C, De Groot K. Stress-absorbing elements in dental-implants. *J Prosthet Dent* 1990;64:198–205.
- [23] Sheets CG, Earthman JC. Natural tooth intrusion and reversal in implant assisted prosthesis: evidence of and a hypothesis for the occurrence. *J Prosthet Dent* 1993; 70:513–20.
- [24] El Charkawi HG, Zekry KA, El Wakad MT. Stress analysis of different osseointegrated implants supporting a distal extension prosthesis. *J Prosthet Dent* 1994; 72:614–22.
- [25] Sheets CG, Earthman JC. Tooth intrusion in implant-assisted prostheses. *J Prosthet Dent* 1997;77:39–45.
- [26] Mensor MC, Ahlstrom RH, Scheerer EW. Compliant keeper system replication of the periodontal ligament protective damping function for implants: part I. *J Prosthet Dent* 1998;80:565–9.
- [27] Ödman J, Lekholm U, Jemt T, Thilander B. Osseointegrated implants as orthodontic anchorage in the treatment of partially edentulous adult patients. *Eur J Orthop* 1994;16:187–201.
- [28] American Association of Orthodontists. Glossary of orthodontic terms. Available at: <http://www.braces.org/braces/dentists/glossary/index.cfm>. Accessed March 2003.
- [29] Sarver DM, Proffit WR, Ackerman JL. Diagnosis and treatment planning in orthodontics. In: Graber TM, Vanarsdall RL, editors. Orthodontics current principles and techniques. St. Louis: Mosby-Yearbook; 2000. p. 73–116.
- [30] Proffit WR, Bailey LJ, Phillips C, Turvey TA. Long-term stability of surgical open-bite correction by Le fort I osteotomy. *Angle Orthodontist* 2000;70:112–7.
- [31] Holdaway RH. A soft-tissue cephalometric analysis and its use in orthodontic treatment planning, part I. *Am J Orthod* 1983;82:279.
- [32] Holdaway RH. A soft-tissue cephalometric analysis and its use in orthodontic treatment planning, part I. *Am J Orthod* 1984;82:279–86.

- [33] Genecov JS. Development of the nose and soft tissue profile. *Angle Orthodontist* 1990;60:191-8.
- [34] Subtekný JD. A longitudinal study of soft-tissue facial structures and their profile characteristics, defined in relation to underlying skeletal structures. *Am J Orthod* 1959;45:7-22.
- [35] Miller PD. Root coverage using a free soft tissue autograft following citric acid application: I. Technique. *Int J Periodontics Restorative Dent* 1982;2:65.
- [36] Nordland WP. Periodontal plastic surgery: esthetic gingival regeneration. *J Calif Dent Assoc* 1989;17:29-32.
- [37] Nordland WP. The role of periodontal plastic microsurgery in oral facial esthetics. *J Calif Dent Assoc* 2002;30:831-7.
- [38] Cole R, Crigger M, Bogle G, Egelberg J, Selvig KA. Connective tissue attachment to periodontally diseased teeth: a histologic study. *J Periodontal Res* 1980;15:1-9.
- [39] Ring ME. *Dentistry: an illustrated history*. New York: Abradale Press; 1992.
- [40] Branemark PI, Zarb GA, Albrektsson T. *Tissue-integrated prostheses: osseointegration in clinical dentistry*. Chicago: Quintessence; 1985.
- [41] Lekholm U, Van Steenberghe D, Herrmann I, Bolender C, Folmer T, Gunne J. Osseointegrated implants in the treatment of partially edentulous jaws: a prospective 5-year multicenter study. *Int J Oral Maxillofac Impl* 1994;9:627-35.
- [42] Tucker AS, Sharpe PT. Molecular genetics of tooth morphogenesis and patterning: the right shape in the right place. *J Dent Res* 1999;78:826-34.
- [43] Kollar EJ. Histogenetic aspects of dermal-epidermal interactions. In: Slavkin HC, Bavetta LA, editors. *Developmental aspects of oral biology*. New York: Academic Press; 1972. p. 126-49.
- [44] Slavkin HC, Chai Y, Hu CC, Millar-Groff S, Bringas Jr P. Intrinsic molecular determinants of tooth development from specification to root formation: a review. In: Davidovitch Z, editor. *Biological mechanisms of tooth eruption, resorption and replacement by implants*. Birmingham, AL: EBSCO Media; 1994. p. 263-72.
- [45] Bianco P, Robey PG. Stem cells in tissue engineering. *Nature* 2001;414:118-21.
- [46] Ferrari G, Cusella-De Angelis G, Coletta M, Paolucci E, Stornaiuolo S, Cossu G, et al. Muscles regeneration by bone marrow-derived myogenic progenitors. *Science* 1998;279:1528-30.
- [47] Kotton DN, Ma BY, Cardoso WV, Sanderson EA, Summer RS, Williams MC, et al. Bone marrow-derived cells as progenitors of lung alveolar epithelium. *Development* 2001;128:5181-8.
- [48] Mooney DJ, Powell C, Piana J, Rutherford B. Engineering dental pulp-like tissue in vitro. *Biotechnol Prog* 1996;12:965-8.
- [49] Harada H, Kettunen P, Jung HS, Mustonen T, Wang YA, Thesleff I. Localization of putative stem cells in dental epithelium and their association with Notch and FGF signaling. *J Cell Biol* 1999;147:105-20.
- [50] Chai Y, Slavkin HC. Prospects for tooth regeneration in the 21st century: a perspective. *Microsc Res Tech* 2003;60:469-79.