


INTERNATIONALES JOURNAL
FÜR


PARODONTOLOGIE & RESTAURATIVE ZAHNHEILKUNDE



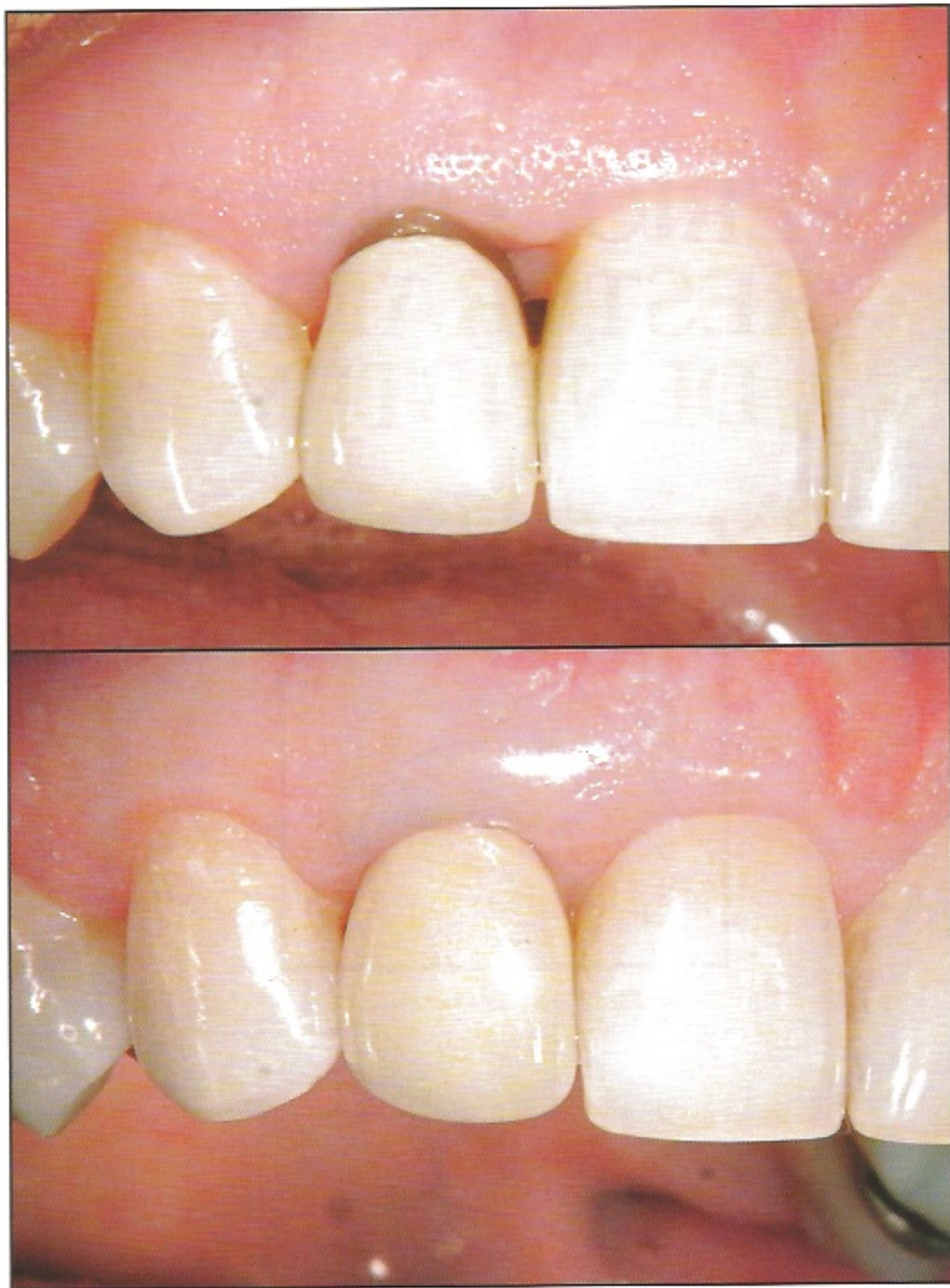28. Jahrgang
Nummer 6
Dezember 2008

THE INTERNATIONAL JOURNAL
OF

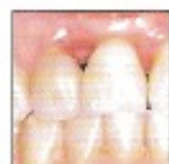PERIODONTICS & RESTORATIVE DENTISTRY



Volume 28
Number 6
December 2008



Microsurgical Technique for Augmentation of the Interdental Papilla: Three Case Reports



W. Peter Nordland, DMD, MS*
Harinder S. Sandhu, DDS, PhD, Cert Perio**

The loss of interdental papillae as the result of trauma or inflammatory periodontal disease creates a significant challenge in the esthetic zone. Conventional surgical techniques are unpredictable because of small working spaces and limited blood supply to the area. Vertical releasing incisions can further jeopardize vascular channels and leave unattractive scarring upon healing. The application of microscopes and microsurgical instruments presents a new frontier for predictable esthetic results. This paper describes a predictable microsurgical technique for reconstruction of the interdental papillae. (Int J Periodontics Restorative Dent 2008;28:543-549.)

*Assistant Professor of Periodontics, Loma Linda University, Loma Linda, California; Private Practice, La Jolla, California; Director of Microsurgery, Newport Coast Oral Facial Institute, Newport Beach, California.

**Professor of Periodontics, Schulich School of Medicine and Dentistry, The University of Western Ontario, London, Canada.

Correspondence to: Dr Peter Nordland, 850 Prospect Street, La Jolla, California, 92037.

The reconstruction of lost interdental papillae remains a challenge. Predictable results are hindered by the small dimensions of the interproximal space and the pattern of vascular supply to this end organ. The swelling of soft tissue during healing as the result of the presence of inflammatory exudates and formation of new capillaries can further jeopardize the positive outcome of papilla reconstruction procedures. Many surgical techniques to augment soft tissue around dental implants¹⁻⁴ and teeth⁵⁻¹⁶ have been described to date. In 1996, Han and Takei¹⁵ described the use of a facial approach with a semilunar incision to gain access to the papillary area for augmentation of the papilla. Cortellini et al^{12,13} proposed a simplified papilla preservation flap that requires a releasing incision in the papillary area and placement of a barrier membrane under the surgical site. Azzi et al⁶⁻⁸ have described techniques to gain access to augment the connective tissue and bone under the deficient papilla. However, these techniques may jeopardize the blood supply to the area.

Numerous clinicians have proposed interdental papilla reconstruc-

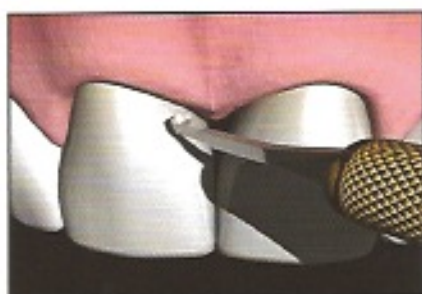


Fig 1 Modification of the micro-scalpel to form a *j* hook.

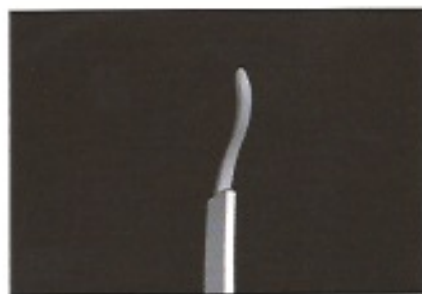

Fig 2 A customized double curve is created to mimic the facial contours, thereby avoiding flap perforation.

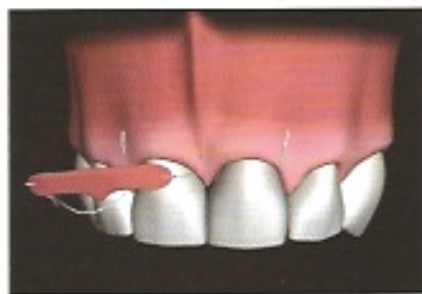

Fig 3 The graft is shaped to produce the needed papillary height and extended laterally to assist in root coverage if needed.

tion techniques, with varying degrees of success.^{5,11,14,16} In a review article, Pini Prato et al¹⁷ concluded that "the predictability of various procedures has not been completely documented, and no data on the long-term stability are available." The aforementioned techniques unfortunately have inherent surgical risk, because the use of releasing incisions will, to some extent, disrupt the adjacent vascular supply. Placement of a releasing incision close to a barrier can cause tenting of the delicate papillary isthmus, and there is potential for exposure of a membrane, a connective tissue graft, or a bone graft. Releasing incisions also risk unesthetic surgical scarring and wound edge necrosis. In sites with a thin, scalloped periodontium, incisions made through delicate papillary tissues increase the risk of failure.

Predictable root coverage procedures focus on enhancement of blood supply at the recipient site, which promotes the survival of the donor tissue.¹⁸ It has long been recognized that a reduction or elimination of releasing incisions will improve vascularity to the

surgical area and enhance the post-surgical outcome. Tunneling surgical approaches can eliminate the need for releasing incisions.¹⁹

This paper describes a microsurgical procedure to position donor tissue under a deficient interdental papilla. The surgery is accomplished without the use of releasing incisions, thereby increasing the likelihood of donor tissue survival and minimizing tissue trauma, excessive bleeding, scarring, and pain. Because the vascular supply remains intact, donor tissue survival is optimized.

Method and materials

The classification of the initial preoperative interdental papilla is determined using the Nordland and Tamow classification scheme.²⁰ This classification helps determine the required volume of tissue. The desired gingivo-incisal height difference is measured using a periodontal probe; the clinician simply measures the distance from the top of the preoperative papilla tip to the desired postoperative papilla tip

location. This will represent the donor tissue thickness that is required to achieve an optimal result.

The interdental papilla is anesthetized, along with the facial gingiva, mucosa, and the palatal gingiva, with xylocaine with epinephrine (1:50,000). Root preparation is accomplished with root planing, and root demineralization and sterilization are performed with tetracycline paste application for 60 seconds.

Creation of space and papillary mobility

The surgical dissecting microscope is used to visualize the morphology of the entire interdental papilla area. A circumferential sulcular incision is made to the crest of the bone using a micro-scalpel with a blade width of 0.9 mm (Nordland Papillae N-6900 Micro-Scalpel, Sable Industries). A sulcular incision is made to the crestal bone, severing the marginal gingiva. This incision extends circumferentially around the adjacent teeth. Surgical magnification will help the surgeon

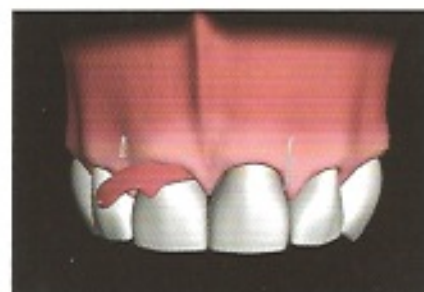

Fig 4 Lasso sutures gently pull the ends of the graft into position.

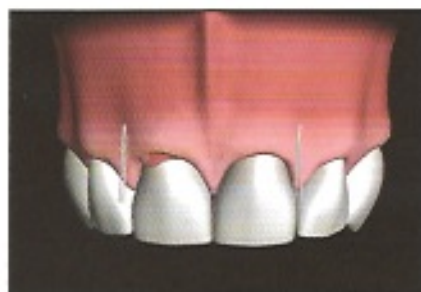

Fig 5 Manipulation of the graft using lasso sutures.

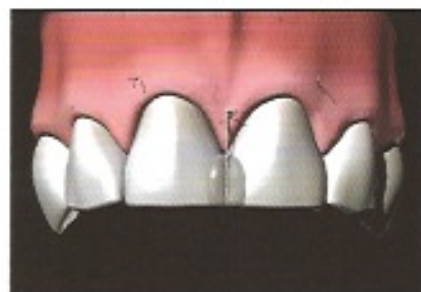


Fig 6 The suspensory suture.

avoid inadvertent severing of the delicate papillary isthmus.

The micro-scalpel blade can be modified to form a j-hook configuration to allow it to completely undermine the delicate papillary tissue (Fig 1). Following the minimal circumferential sulcular incision, a split-thickness flap is prepared. Custom modification of the micro-scalpel allows for individual variations. A second micro-scalpel is modified to mimic the subtle facial contours of the buccal gingiva (Fig 2). This allows the surgeon to extend the sulcular incision facially up to and past the mucogingival junction. Once the incision extends past the mucogingival junction, mobility of the undermined tissue can be achieved. Mobility is essential to allow for the creation of space under the papilla to receive a dense fibrous connective tissue graft. Although it is difficult to achieve, some laxness of palatal tissue is obtained as well. The surgeon needs to verify that the dissection is sufficient to allow the manipulation of the papilla with a curette into the desired new location. An adequate volume of donor tissue must be procured corresponding to the space created.

The donor site

The surgeon must determine exactly how much donor tissue will be necessary using the initial preoperative gingivo-incisal height compared to the desired new papilla location. Dense fibrous connective tissue is most desirable for augmentation. Bone sounding can be performed (surface to palatal bone) to locate donor tissue of adequate dimensions. If a large volume of papillary tissue is required, the maxillary tuberosity will frequently be the donor site of choice because of its fibrous nature and thickness. The donor tissue is harvested, with the desired dimensions of the new papilla to be created kept in mind. Often the papillary shape can be reproduced by harvesting the papillary tissue between the second premolar and first molar as a gingival unit transfer.⁵ Facial length extension of the donor tissue is desirable so that a significant number of intact vascular channels of the donor tissue are retained (Fig 3). This tissue harvesting technique creates a large mass of donor tissue, even though the interdental papilla to be augmented is

small. The use of a large mass of tissue means that the survivability of the small interdental graft can be enhanced because of the larger surface area available for nutrition from blood perfusion.

The donor tissue is shaped to reproduce the height, width, and pyramidal contour of the deficient papilla being augmented. Lateral extensions of the donor tissue can be used to create root coverage for the adjacent teeth, if desired.

Positioning and stabilizing the graft

A "lasso" suture is used to help pull and position the ends of the donor tissue. Ideally a 7-0 or 8-0 expanded polytetrafluoroethylene (e-PTFE) suture (Gore-Tex, W. L. Gore) is used because of its small size, tensile strength, and biocompatibility. Sutures are positioned through the tunnel (as shown in Figs 3 to 5) to gently pull the donor tissue into position and anchor it. A resorbable suture can also be used to assist in the positioning of the graft under the deficient papilla. Positioning

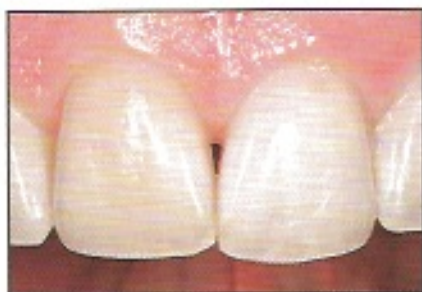

Fig 7a Class I loss of papilla selected for surgical correction.

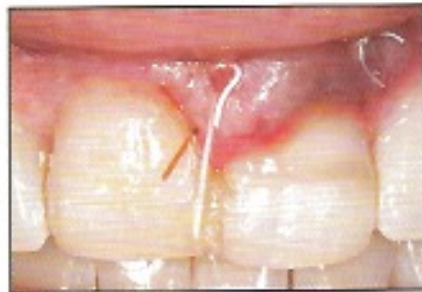

Fig 7b Seven-day postoperative view showing the connective tissue secured by a gut suture, a suspensory suture, and a lateral positioning suture.

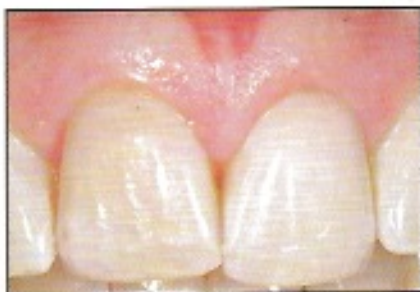

Fig 7c Eight-week postoperative view showing improvement of papillary height.

of the graft under the interdental papilla can be challenging, but it is critical to the success of the procedure. The graft can be gently pulled into position with a suture that begins at the palatal gingiva; goes under the papilla, lassoing the graft; and then is run back through to the palatal gingiva to be tied off.

The suspensory suture

Wound tension can apply forces to the graft and surrounding tissues as they heal. Lip musculature such as the orbicularis oris muscle and tissue memory can create pressure and tension on the overlying tissue and thereby create a tendency to pull the papillary tissue back to its original position. To preserve this new papillary tissue position, a "suspensory suture" is used. A suspensory suture (Fig 6) that begins at the base of the papilla and is anchored around the interproximal contact point is essential to maintain the new position and height of the papilla. The suspensory suture starts by piercing the facial papillary base,

proceeds through the connective tissue graft, and exits through the base of the palatal papilla. The addition of composite bonding material at the interproximal contacts of the adjacent teeth may help prevent this suspensory suture from slipping through the interproximal contact. The suspensory suture is anchored by being looped around the bonded contact point. If this suture is not used, then retraction of the tissue usually occurs. Placement of a surgical dressing is usually not necessary, but the patient is instructed to use a chlorhexidine mouth rinse during tissue healing and maturation.

Clinical cases

Three clinical examples are included to demonstrate this surgical technique and its long-term success. The first patient had undergone orthodontic treatment to close the embrasure space. Ankylosis of the maxillary right central incisor inhibited total movement. The patient was then referred for microsurgical correction (Fig 7).

The second patient (Fig 8) demonstrated success using the technique described in this paper along with restorative widening of the mesiodistal dimension with the help of veneers. The patient had experienced four unsuccessful attempts at surgical repair before referral for microsurgical correction. The results shown were achieved after only one microsurgical procedure. The site demonstrated stability after 6 years of follow-up (Fig 8e).

The third patient (Fig 9) demonstrates a cosmetic papillary defect created by a surgical incision. A horizontal depression existed where an incision was made and tissue was removed. Patient discontent, root exposure, and papillary loss were the consequences. A one-stage surgical correction was achieved. Later, after normal tissue contours were achieved, a new crown was placed. This patient had an uneventful 3-year follow-up (Fig 9b).

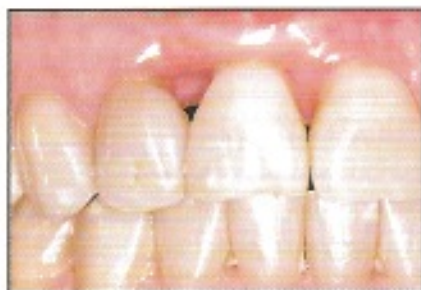

Fig 8a Class III situation involving a 2-mm loss of papilla requiring a multidisciplinary approach for an esthetic result. The maxillary right central incisor had extruded. Note the incisal edge wear of the central incisor and the restorative buildup of the mesial side of the lateral incisor. The patient's history included four previously failed attempts; each failure resulted in larger defects.

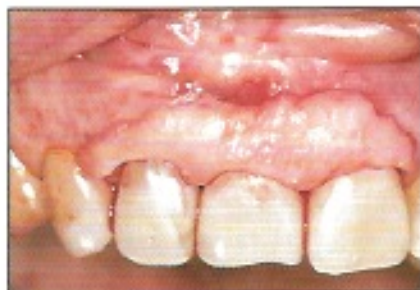

Fig 8b The volume of connective tissue graft used for papilla reconstruction is demonstrated as the tissue is laid over the surgical site. The graft is sized and contoured as needed.

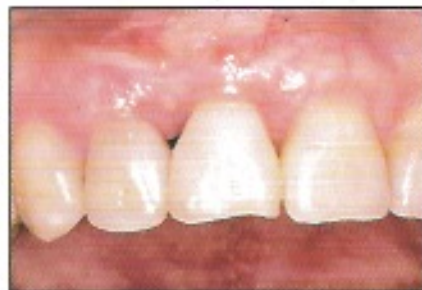

Fig 8c View at 6 weeks postsurgery indicates improvements in closure of the papillary space. Previous extrusion of the central incisor decreased the mesiodistal dimension at the gingival level, necessitating restoration. (Figures 8a to 8c are reprinted from the Journal of the California Dental Association 2002;30:831-837.)

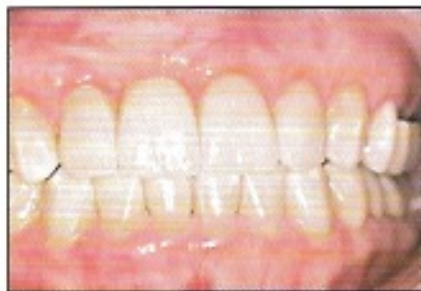

Fig 8d (left) Porcelain veneer restorations are used to completely close the embrasure space.

Fig 8e (right) Six-year postoperative follow-up showing healthy tissue.

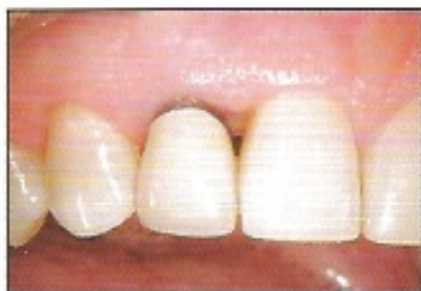
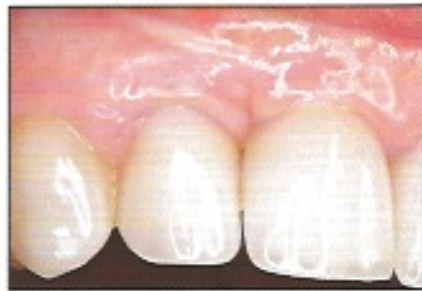
Fig 9a Previous periodontal pocket reduction surgery had created a Class III situation: 1 mm of papilla loss on the mesial surface of the maxillary right lateral incisor, root exposure, and an unesthetic outcome.

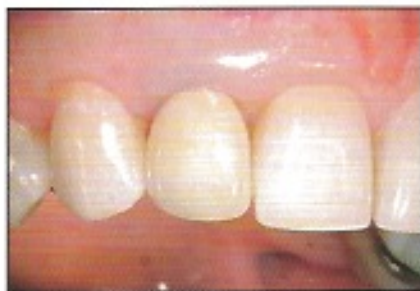

Fig 9b Three-year postoperative follow-up after microsurgery and placement of a new crown on the lateral incisor demonstrates complete restoration of the lost papillary anatomy.

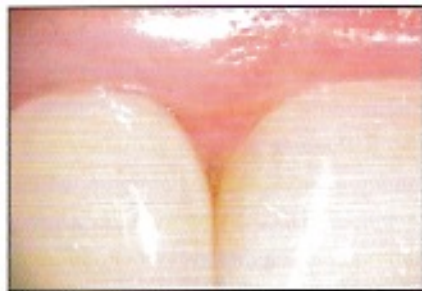

Fig 9c Close-up view of restored/grafted papilla anatomy.

Discussion

Although several papers describe the benefits gained using the surgical dissecting microscope, well-controlled studies must be accomplished to determine whether surgical magnification does enhance outcomes.^{21,22}

Does the suspensory suture matter?

The coronally positioned flap is kept in its new position by releasing the flap from underlying tissues, and coronal suturing of the flap. In the technique presented, no vertical incisions are used. The authors rely on the thorough release of the buccal and palatal flaps by microsurgical dissection and the placement of suspensory sutures. More importantly, the suspensory suture maintains the donor tissue under the papilla and in a coronal position until the overlying flap has matured at its postsurgery position, thus preventing apical migration or displacement of the graft.

If there is a large papillary deficiency, a large amount of tissue will be required to fill the space. A large graft can be challenging to position through the sulcular incision. A small papillary deficiency presents other problems stemming from limited access into tiny spaces.

A thin, scalloped gingival unit is usually very delicate, and gentle manipulation of the tissues and micro-scalpels can prevent inadvertent severing of delicate tissues. The laxness of the buccal and palatal flaps and the use of lasso sutures are critical in ensur-

ing success. The graft tissue must be contoured precisely for the individual site before the clinician can attempt to position it into the papillary tunnel. Thick, fibrous tissue is the tissue of choice for papilla reconstruction.

Because of the small dimensions of the interdental papilla and the limited access, surgical magnification and microsurgical instruments are recommended, as they assist the surgeon by increasing visibility, eliminating unnecessary releasing incisions or unintentional incisions, and facilitating access, thus improving the predictability of the process.

The suspensory suture supports the graft in its new position for the first two weeks after surgery. The suture should be placed at the papillary base to avoid tearing of the papilla. The use of e-PTFE sutures allows the surgeon to tighten the suture gently as the surgeon's knot slides on itself to achieve ideal tension.

The use of a specially modified scalpel and magnification are of critical importance in the success of this procedure. A micro-scalpel allows the surgeon to lift the flaps from underlying tissues without injury while avoiding vertical incisions, thus maintaining vascularity to the surgical area. Burkhardt and Lang²¹ have shown superior vascularity and enhanced treatment outcomes with microsurgery. Once it is modified into a j hook, the micro-scalpel allows tunneling under the interdental papilla without splitting the buccal and lingual halves. A conventional scalpel that cannot be bent may not allow this precision. Belcher²³ has discussed the advantages of microsurgery techniques. Suturing material

must retain its tensile strength and the needle must be sharp and precise to avoid excessive trauma to overlying tissue. During the postoperative period, wooden and metal interproximal cleaning tools that can compress the papillary tissue must be avoided.

Orthodontic tooth movement can create open gingival embrasure spaces²⁴ compromising the esthetic outcome of adult orthodontic tooth alignment. Alternatively, orthodontic root approximation can also help to close an open embrasure space. Other treatment modalities for embrasure space closure can include restorative reshaping of the adjacent teeth as well as surgical addition as described. The authors' experience relates that surgical intervention is most helpful when the cause of the papillary loss is a result of a previous surgical insult. The clinician must evaluate all of the causative parameters to choose the appropriate treatment modality in each individual case.

References

- Jemt T. Regeneration of gingival papillae after single-implant treatment. *Int J Periodontics Restorative Dent* 1997;17:326-333.
- Palacci P. Peri-implant soft tissue management. Papilla regeneration technique. In: Palacci P, Ericsson I, Engstrand P, Rangert P (eds). *Optimal Implant Positioning and Soft Tissue Management for the Brånemark System*. Chicago: Quintessence, 1995: 59-70.
- Takoi HH, Han TJ, Carranza FA Jr, Kenney EB, Lekovic V. Flap technique for periodontal bone implants. Papilla preservation technique. *J Periodontol* 1985;56: 204-210.
- Tinti C, Benfenati SP. The ramp mattress suture: A new suturing technique combined with a surgical procedure to obtain papillae between implants in the buccal area. *Int J Periodontics Restorative Dent* 2002;22: 63-69.
- Allen AL. Use of the gingival unit transfer in soft tissue grafting: Report of three cases. *Int J Periodontics Restorative Dent* 2004;24: 165-175.
- Azzi R, Etienne D, Carranza F. Surgical reconstruction of the interdental papilla. *Int J Periodontics Restorative Dent* 1998;18: 466-473.
- Azzi R, Etienne D, Sauvan JL, Miller PD. Root coverage and papilla reconstruction in Class IV recession: A case report. *Int J Periodontics Restorative Dent* 1999;19: 449-455.
- Azzi R, Takoi HH, Etienne D, Carranza FA. Root coverage and papilla reconstruction using autogenous osseous and connective tissue grafts. *Int J Periodontics Restorative Dent* 2001;21:141-147.
- Beagle JR. Surgical reconstruction of the interdental papilla: Case report. *Int J Periodontics Restorative Dent* 1992;12:145-151.
- Blatz MB, Hürzeler MB, Strub JR. Reconstruction of the lost interproximal papilla—Presentation of surgical and non-surgical approaches. *Int J Periodontics Restorative Dent* 1999;19:395-406.
- Carnio J. Surgical reconstruction of interdental papilla using an interposed subepithelial connective tissue graft: A case report. *Int J Periodontics Restorative Dent* 2004;24:31-37.
- Cortellini P, Pini Prato GP, Tonetti MS. The modified papilla preservation technique. A new surgical approach for interproximal regenerative procedures. *J Periodontol* 1995;66:261-266.
- Cortellini P, Pini Prato GP, Tonetti MS. The simplified papilla preservation flap. A novel surgical approach for the management of soft tissues in regenerative procedures. *Int J Periodontics Restorative Dent* 1999;19: 589-599.
- Francetti L, Del Fabbro M, Testori T, Weinstein RL. Periodontal microsurgery: Report of 16 cases consecutively treated by the free rotated papilla autograft technique combined with the coronally advanced flap. *Int J Periodontics Restorative Dent* 2004;24: 272-279.
- Han TJ, Takoi HH. Progress in gingival papilla reconstruction. *Periodontol* 2000 1996; 11:65-68.
- Nemcovsky CE. Interproximal papilla augmentation procedure: A novel surgical approach and clinical evaluation of 10 consecutive procedures. *Int J Periodontics Restorative Dent* 2001;21:553-559.
- Pini Prato GP, Robundo R, Cortellini P, Tinti C, Azzi R. Interdental papilla management: A review and classification of the therapeutic approaches. *Int J Periodontics Restorative Dent* 2004;24:246-255.
- Langer B, Calagna LJ. The subepithelial connective tissue graft. A new approach to the enhancement of anterior cosmetics. *Int J Periodontics Restorative Dent* 1982;2: 22-33.
- Zabalegui I, Sicilia A, Cambra J, Gil J, Sanz M. Treatment of multiple adjacent gingival recessions with the tunnel subepithelial connective tissue graft: A clinical report. *Int J Periodontics Restorative Dent* 1999;19: 199-206.
- Nordland WP, Tarnow DP. A classification system for loss of papillary height. *J Periodontol* 1998;69:1124-1126.
- Burkhardt R, Lang NP. Coverage of localized gingival recessions: Comparison of micro- and macrosurgical techniques. *J Clin Periodontol* 2005;32:287-293.
- Shanelec DA. Periodontal microsurgery. *J Esthet Restor Dent* 2003;15:402-407; discussion 408.
- Belcher JM. A perspective on periodontal microsurgery. *Int J Periodontics Restorative Dent* 2001;21:191-196.
- Kurth JR, Kokich VG. Open gingival embrasures after orthodontic treatment in adults: Prevalence and etiology. *Am J Orthod Dentofacial Orthop* 2001;120:116-123.